

Original Article

Evaluation of Wound Healing Effects of Scrophularia Striata Seed Extract in Rat

Mohammad Reza Sabahi¹, Mehrdad Taghipour^{2*}, Mehdi Nouredini³, Seyed Mohammadreza Javadi².

1. Department of general surgery, Qom University of Medical Sciences, Qom, Iran

2. Department of General Surgery, Besat Hospital, Hamadan University of Medical Sciences, Hamadan, Iran.

3. Physiology Research Center, Kashan University of Medical Science, Kashan, Iran.

*correspondence: **Mehrdad Taghipour**, MD, Department of General Surgery, Besat Hospital, Hamadan University of Medical Sciences, Hamadan, Iran. Email: mehrdadtaghipour@gmail.com

Abstract:

Introduction: Wound healing is a complex process that can be disrupted by different factors. Currently, there is no standard product to accelerate wound healing in incisional wounds. Acceleration of wound healing by *Scrophularia striata* (SS) hydroalcoholic extract was shown in previous studies. This study was designed to show the effect of SS seed aqueous extract on tissue tension and surface area of the healing wound in rats.

Methods: One hundred rats (Sprague Dawley -200±50 gr weight) were randomly assigned into 5 groups of 20 cases. Eucerin (negative control), phenytoin 1 percent cream (positive control), and SS root aqueous extract in Eucerin base (SSRE) 1 µg/ml, 10 µg/ml and 100 µg/ml. The incisional wound was inflicted on the spinal interscapular area. It was treated with substances on a daily basis. Tissue tension and the wound area was measured in all subjects.

Findings: In our study, the most tensile resistance of the healing wound was observed in group 4. Interestingly, group 4 showed the least surface area of the wound after the completion of the treatment period. Overall, there was a significant difference in wound healing process between groups that received SSRE treatment and other groups.

Conclusion: SSRE increases scar tissue endurance and improves wound healing. Early closure of the wound and increased tension endurance can help prevent future wound complications.

Keywords: *Scrophularia striata*, Sprague Dawley rats, Phenytoin, Eucerin, Tissue Tension.

Introduction:

Defective wound healing is one of the most important problems in hospitalized patients (1). This could be due to many factors including infection of the wound site, shortage of cells involved in healing process or inappropriate granulation tissue appearance (2). Wound healing is a complex

process which is dependent on many factors. Interplay between Blood, endothelial and skin cells with serum enzymes play a major role in this biochemical, physiological and morphological process. Wound healing consists of three consecutive stages, inflammation, proliferation and maturation. The final product of maturation stage results in normal integration of the damaged tissue

(3). One of the factors in which the normal integration is evaluated is the endurance to external tension. This endurance results from a complex collagen matrix made by fibroblasts (4). Naturally, fibroblasts increase in number and activity in wound site. Fibroblast aggregation could also be stimulated by both synthetic and herbal (e.g. extract of *Bridelia ferruginea* leaf.) products (5). It is shown that phenytoin cream causes an increase in scar tissue tensile resistance while used topically. The mechanism behind this effect is still unknown (6 and 7). On the other hand, speed of wound healing is measured by decrease in wound surface area over time. This parameter is the final result of all mechanisms involved in wound healing. It is shown that *Scrophularia striata* hydroalcoholic extract accelerates open wound healing in rabbits and mice. This was illustrated as shorter time for complete wound closure and faster decrease in wound surface area over time (8, 9). At present time, there is no standard of care in using a specific chemical product to accelerate healing process in incisional wounds. Previous studies showed that application of many plants' products including jujube extract, *Artemisia* extract, Aloe Vera gel, Alfa extract, Lavender cream, *Scrophularia striata* plant, Mummy, Green tea and Chamomile essential oil were effective in acceleration of healing process (9-11). The aim of our study is to evaluate the effect of *Scrophularia striata* seed extract on wound healing by measuring tissue tension and wound surface area over time.

Methods:

One hundred healthy rats (Sprague Dawley - 200±50 gr weight) were purchased from Razi institution. Rats were kept in standard bins according to international standards for care of experimental animals. Food and water were provided ad lib. Research Ethics committee approved our study. They were randomly divided to five experimental groups: 1-Eucerin (negative control), 2-phenytoin 1 percent cream (positive control), and 3-*Scrophularia striata* root aqueous extract (SSRE) in Eucerin base 1 µg/ml, 4- SSRE 10 µg/ml and 5- SSRE 100µg/ml). In day zero, Subjects were shaved in spinal interscapular area by electrical machine. Additional shaving was done using shaving blade. Incision site was defined using anatomical landmarks and was marked by black ink. Subjects were immobilized on surgical table by scotch tape. Anesthesia was induced by injecting Ketamine and Rompan in peritoneal cavity. A 2×2 cm circular incision was made by a surgical blade inside the limits of the shablon placed on incision site. Additional tissue dissection was done using surgical scissors. Incision site was kept clean by application of sterile gauze and daily dressing. Incision was treated with 1, 10 and 100µg/m *Scrophularia striata* root extract in groups 3, 4 and 5, phenytoin 1 percent cream in group 2 (positive control) and Eucerin in group 1 (negative control). On days 3,5,7,9,11,13,15,17,19,21 and 23, the incision was photographed using digital camera. The camera lens was placed 20cm perpendicular to the subjects on a constant lever. The wound area was calculated by ImageJ® Softonic version K 1.45 using digital photographs. On days 6, 12, 18 and

23, five rats from each group were euthanized for tissue sampling purposes. Selection was based on their ordinal numbers. The incision site with 0.5cm margin of intact skin was dissected. Tissue tension was measured using tensiometer device on tissue sample (10 and 11, 69).

Findings:

All animals completed our study without any unexpected loss. Scar tissue tension resistance was compared between all groups in days 1, 6, 12, 18 and 23 (figures 1- 4). Wound surface area was compared between all groups in days, 5, 7, 9,11,13,15,17,19,21 and 23 (figures 5-8). Overall, our results indicate that in all groups, changes in tension resistance and surface area do not follow a steady pattern. All groups show improvement in tension resistance and wound surface area by the end of the study regardless of the treatment regimen. Groups 3,4 and 5 showed statistically significant difference in both parameters comparing to group 1 and 2. Group 4 (10 µg/ml *Scrophularia striata* seed extract) had the best results in both variables comparing to all other groups.

Discussion:

According to WHO (World Health Organization), eighty percent of population in Asian and African countries use plant products for their primary health problems. The prospective of their usage varies from treatment of general health problems to burn and wound care (12, 13). Nowadays, herbal medicine is used as an alternative to western medicine in Iran (14). The result of our study shows that topical usage of *Scrophularia striata* seed extract on

incisional wounds significantly improves ($P<0.05$) wound healing comparing to phenytoin one percent cream (positive control) or Eucerin (negative control). This effect is dose dependent in which 10µg/ml *Scrophularia striata* seed extract showed the best result amongst all experimental groups. Additionally, wound improvement starts sooner while using 10µg/ml solution. Topical use of phenytoin cream on incisional wounds shows improvement in wound healing. This effect is more pronounced in case of increased scar tissue tensile resistant (15, 16). The molecular mechanism by which Phenytoin exerts its effect is under debate although some researchers have presented a role in neovascularization in wound site (17). This effect might also be due to acceleration of granulation tissue formation or collagen deposition in wound site (18). Eucerin cream is an emollient with no direct effect on wound healing process. It is always used as neutral substance in negative control groups in wound studies (19). Shohany et al., showed that aqueous extract of *Scrophularia striata* plant accelerates wound healing in rabbits. His study supports the results of our experiment (20). Adetutua et al., reported that extract of *Bridelia ferruginea* leaf increases the number of fibroblasts in wound site (21). Ardeshiri et al., showed that this effect is partially due to the active flavonoid substance in plant extract (22). We did not incorporate pathological studies in our experiment, so this might be the underlying pathophysiology of accelerated wound healing in our study. Future experiments are needed to prove this theory as well.

Conclusion:

The results obtained from this study showed that SS root aqueous extract in Eucerin base increased scar tissue endurance and improved wound healing. Moreover, early closure of the wound and increased tension endurance can help prevent future wound complications. All of these processes can be demonstrated through pathophysiological mechanisms and will be established in future studies.

References:

1. Seymour I.Schwartz. The principles of surgery. Macgraw-hill.9th ed.2010, 345-369
2. Lawrence W.Way. Current surgical diagnosis & treatment.Lange.4th ed. 2010,458-462
3. Bayat M., Razavi SN, Ahmadi H, Peyrovi H., Sadeghi Y, Kazemi B. The effect of therapeutic ultrasound on the healing of full thickness skin wounds in rabbit dermal region. Hakim 2001;3:117-124.
4. Shojaei H, Xu Nooshafarin Kazemi, Mohammad Hassan a. Reported a case of ulcers refractory to conventional therapy in spinal cord injured patients with low power laser. Veteran Medical Journal 1387;1:85-90
5. Ashraf K, Esmali E, Shahinfard N, Ansari R, Parvin N, Namjoo A, et al. The effect of hydroalcoholic extracts of Zizipus vulgaris L. on burn healing. J Shahrekord Univ Med Sci 2011;12: 78-82.
6. Muhammad Ali Tavakoli, F. Bani Assad, Arab, Mehdi Mahmoudi, Hamid Jafari grandson, V. Tavakolian, Mohadeseh Kamali, M. Mahmoudi, S. Mokhtari buck. Effect of Artemisia extract on cutaneous

wound healing in rats. Journal of Mazandaran University of Medical Sciences 2009;20:70-76.

7. Jarahi, M. Khorasani, M. Ajorloo, M, Taheriayn, AA. Local effect of Aloe vera gel (Aloe barbadensis Miller) on incisional wound healing in rat skin. Journal of Gorgan University of Medical Sciences 2009;11:13-17.
8. Jenna khaiay, Hossein Rafiee, M. Farhood. Alfa extract on wound healing in the rabbit ear cartilage. Journal of Medical Sciences (AMUJ) 1388;12:15-24.
9. Khadivzadeh T., M. Maleki, M., H. R., Muhammad Khwaja bucket. Lavender cream effect on episiotomy pain and wound healing in primiparous women. J Mashhad School Nurs Midw 2009;9:19-24.
10. Shooohani B, Hemati AA, Taheri Moghadam M. Healing of the plant extract “was thirsty” (Scrophularia striata) on open skin wounds in rabbits. Scientific Journal of Ilam University of Medical Sciences 2010;17:9-16.
11. Rezvanipour M. , Pourzadehosseini F. , Malekpour R. , Zarabi A. Mummy effects on some parameters involved in wound healing in mice. Kerman University of Medical Sciences Journal 1386;14:267-277.
12. Parichehr yaghmaei, faeeze Javadi, Mohammad Ali Nilforooshzade, H men, P. Kakanzhadyan. The Effect of Different Doses of Water Green Tea Extract on the Development of Open Wounds in Mice. 2009;18:57-63.
13. Pazandeh F, Savadzadeh S, Mojab F, Alavi Majd H. Effects of Chamomile Essence on Episiotomy Healing in

Primiparous Women. J Ardabil Univ Med Sci 2008;8:364-370.

14. Sewall GK, Robertson KM, Connor NP, Heisey DM, Hartig GK. Effect of topical mitomycin on skin wound contraction. Arch Facial Plast Surg 2003; 5: 59-62.

15. Lajym Ardeshiri A., M. Barzegar, M. Rezaei Tavirani, Hashemi, Sydhdry, Sayyed Hassan Moghaddam, M., SH Reeve. Effect of plant extracts on human fibroblast cells and human fibroblast Astryata. Medical Sciences 2009;19:168-172.

16. Mozafarian VA. [Khuzastan flora: Agriculture natural resources research]. Publication Center of Khuzestan Province. 1999; 353(Persian)

17. Azadbakht M. [Classification of medical plants. Tehran: Teimorzadeh Pub. 2000; 7-276.] Persian

18. Johnston DE. Wound healing in skin, plastic and reconstructive surgery. Vet Clinic North Am 1990;20:1-45.

19. Anthony L. Mescher. Junqueiras basic histology. 12th ed, 2010, 404-425

20. Shohani F. People Journalism of Ivan. Ilam Cultural Heritageorg 2003; 56-7.

21. Adewale Adetutua, Winston A. Morgana, and Olivia Corcorana. Antibacterial, antioxidant and fibroblast growth stimulation activity of crude extracts of *Bridelia ferruginea* leaf, a wound-healing plant of Nigeria. Journal of Ethnopharmacology 2011;133:116-119.

22. Abdoreza Ardeshiri-Lagimi, Mansoreh Barzegar, Mostafa Rezaei-Tavirani and et al. Effects of *Scrophularia striata* extract on human fibroblast cells. Medical Sciences 2009; 19: 168-172.

Tables and Charts:

Figure 1: Group 3 effect on tissue tension on days 6, 12, 18 and 23. *Scrophularia striata* (sl). Eucerin (o). Phenytoin (f). Each bar represents 5 cases. $P < 0.05^*$, $P < 0.01^{##}$ and $P < 0.001$.

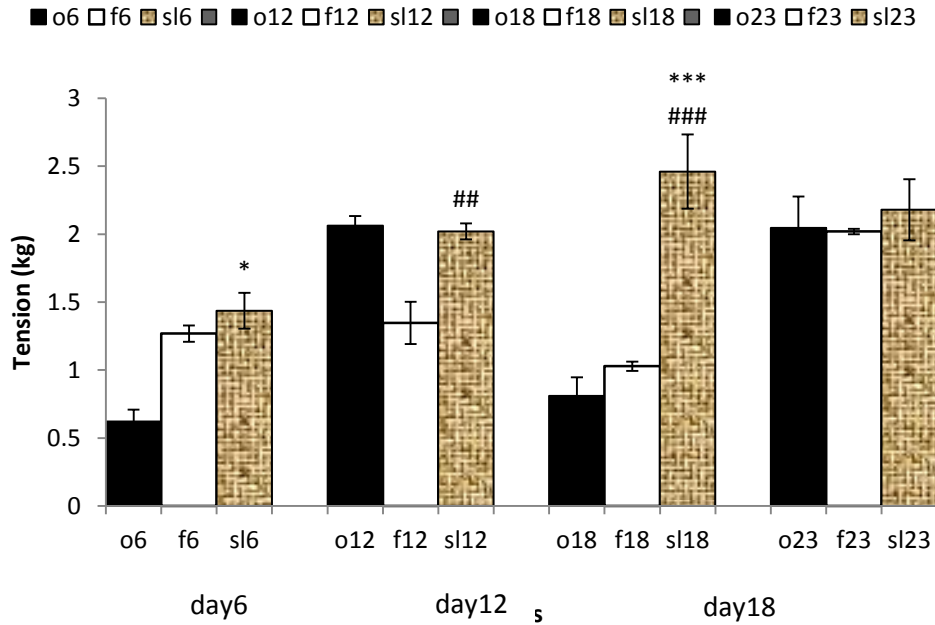


Figure 2: Group 4 effect on tissue tension on days 6, 12, 18 and 23. *Scrophularia striata* (sm). Eucerin (o). Phenytoin (f). Each bar represents 5 cases. $P < 0.05$ *, $P < 0.001$ ### and $P < 0.001$.

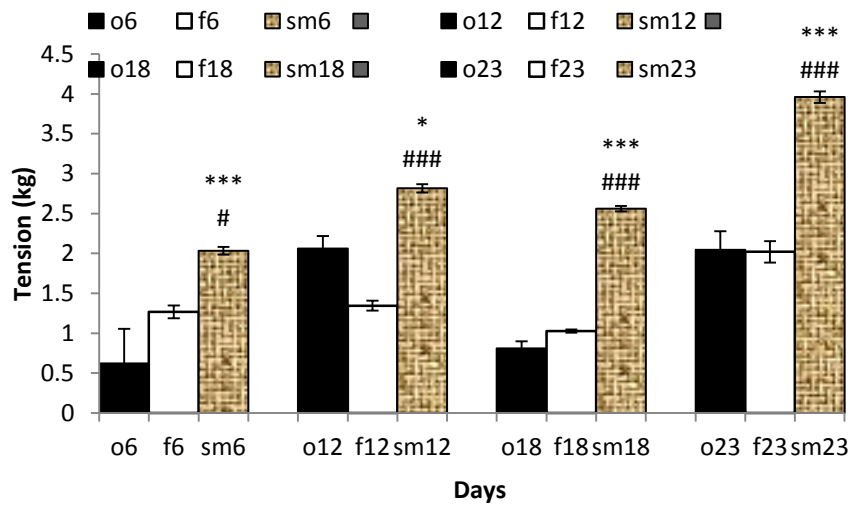


Figure 3: Group 5 effect on tissue tension on days 6, 12, 18 and 23. *Scrophularia striata* (sh). Eucerin (o). Phenytoin (f). Each bar represents 5 cases. $P < 0.001$ ### and $P < 0.001$.

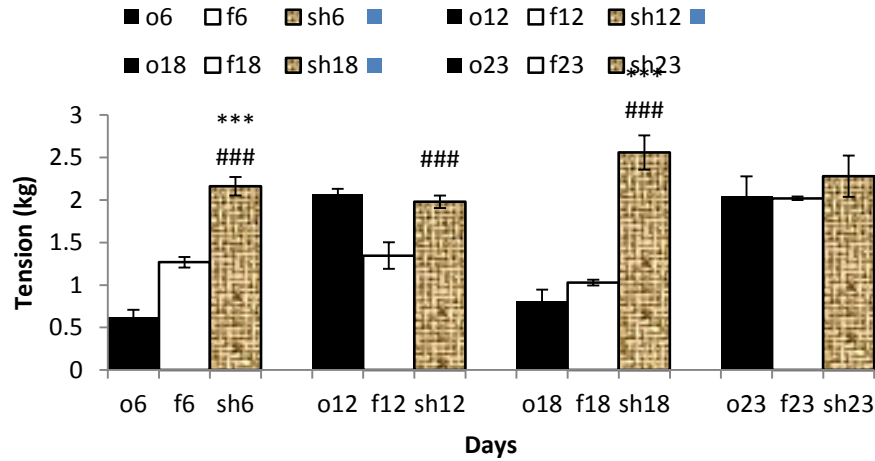


Figure 4: Groups 3,4 and 5 effect on tissue tension on days 6, 12, 18 and 23. 1 µg/ml (sh). 10 µg/ml (sm).100 µg/ml (sl). Each bar represents 5 cases. P<0.01**, P<0.01###, P<0.01## and P<0.001.

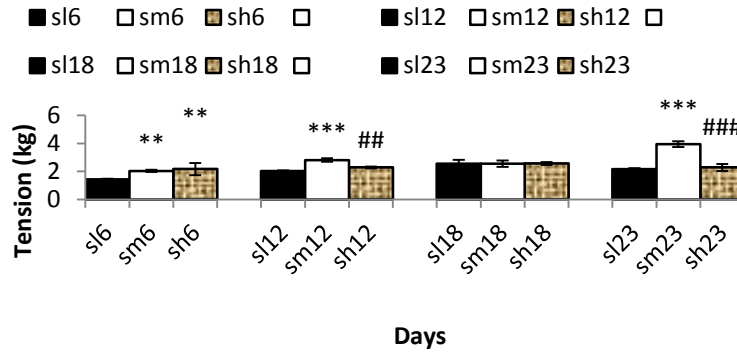


Figure 5: Group 3 effect on wound area on days 1, 3, 5, 7, 9, 11, 13, 15, 17, 19 and 21. Scrophularia striata (yellow bars). Eucerin (o). Phenytoin (f). Each bar represents 5 cases. P<0.01**, P<0.001***. P<0.05##. P<0.01####. P<0.05.

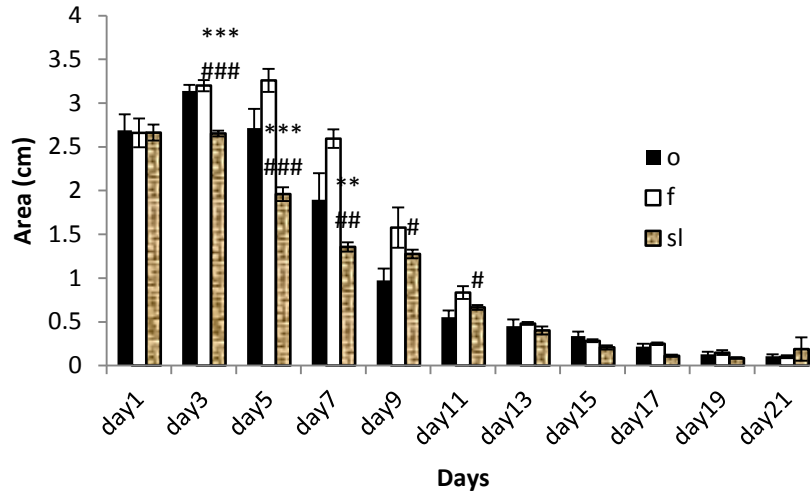


Figure 6: Group 4 effect on wound area on days 1, 3, 5, 7, 9, 11, 13, 15, 17, 19 and 21. Scrophularia striata (yellow bars). Eucerin (o). Phenytoin (f). Each bar represents 5 cases. P<0.01**, P<0.001***, P<0.01##, P<0.001.

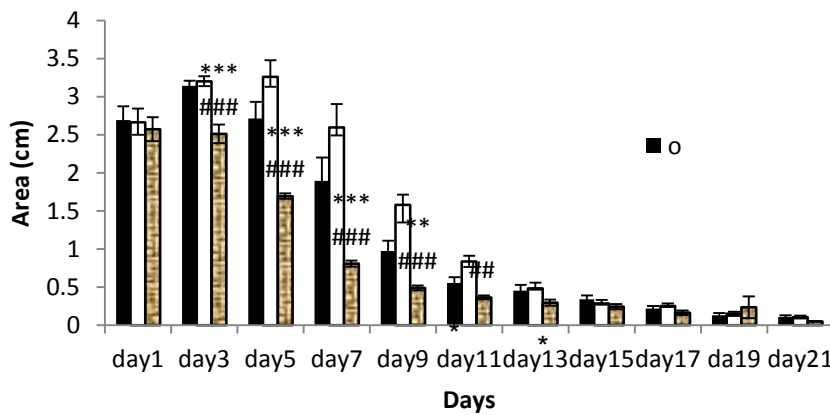


Figure 7: Group 5 effect on wound area on days 1, 3, 5, 7, 9, 11, 13, 15, 17, 19 and 21. Scrophularia striata (yellow bars). Eucerin (o). Phenytoin (white bars). Each bar represents 5 cases. P<0.01##, P<0.05.

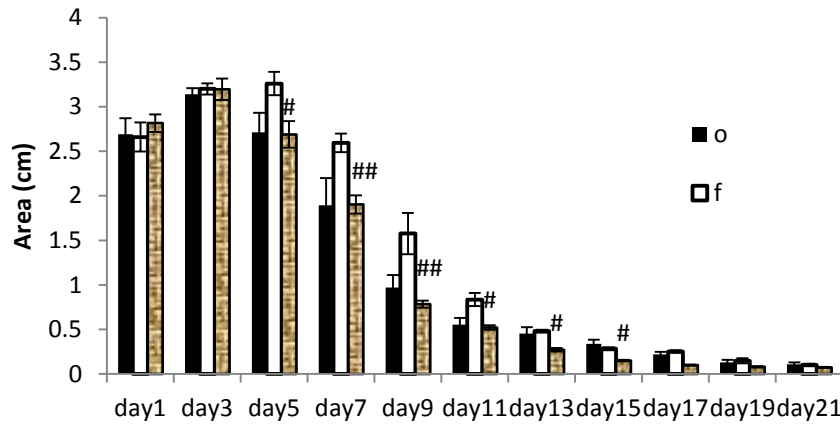


Figure 8: Group 3,4 and 5 effect on wound area days 1, 3, 5, 7, 9, 11, 13, 15, 17, 19 and 21. 1 µg/ml (sl). 10 µg/ml (sm).100 µg/ml (sh). Each bar represents 5 cases. P<0.01**, P<0.001###, P<0.01## and P<0.001.

