

Case Report

A Case Report and Review of the Pathophysiologic Role of Corpus Callosum Agenesis in Intraventricular Hemorrhage

Vahid Mogharab, PhD 1, Farshid Javdani, MD 2, Naser Hatami, MD 2*, Pouyan Keshavarz MSc 2.

1. Pediatrician. Department of Pediatrics, Jahrom University of Medical Sciences, Jahrom, Iran.
2. Student Research Committee, Jahrom University of Medical Sciences, Jahrom, Iran.

*correspondence: **Naser Hatami**, Medical student, Jahrom University of Medical Sciences, Shahid Motahari Street, Jahrom, Iran. Email: naserohatami@gmail.com

Abstract:

Background: The agenesis of corpus callosum (ACC) is referred to a complete or partial defect in the formation of corpus callosum which is a commissure between brain hemispheres. It is a rare disease that can produce a wide range of syndromes and symptoms.

Case Presentations: we present a case of newborn baby Iranian girl who had agenesis of corpus callosum. Severe atrophy of brain and Intraventricular hemorrhage in the preterm neonate was reported. Dilation of lateral ventricles and third ventricle, as well as moderate hydrocephaly and subdural effusion, were recorded in medical ultrasound studies. The brain CT scan also indicated Intraventricular hemorrhage (grade IV) and severe brain atrophy.

Keywords: Agenesis of Corpus Callosum; Intraventricular Hemorrhage; Brain Atrophy; Birth Defect.

Introduction:

The agenesis of corpus callosum (ACC) is the state of complete or partial absence in formation of corpus callosum. ACC is a rare disease with an incidence of approximately 0.05-0.7% in general population(1, 2). It is a heterogeneous and rare neurological condition which can be seen alone or in combination with other brain disorders. Prosencephalic disorders cause some congenital diseases such as agenesis of the corpus callosum(3). The diagnosis of this disorder is often characterized by medical ultrasound in pregnancy follow up. ACC diagnosis is usually not possible before 18 to 20 weeks of pregnancy because the corpus callosum is still incomplete(4, 5). The most common brain disorder detected by routine

medical ultrasound at 22 weeks of pregnancy is ACC. ACC can be due to teratogen and infectious agents. Fetal alcohol spectrum disorder is also a risk factor for ACC infection(6, 7). Chromosomal abnormalities and genetic syndromes are reported in 10% and 20-35% of cases respectively. The ACC can be complete or partial, either isolated or associated with other abnormalities (such as cerebral growth disorders, intracranial cysts, eye problems, facial, cardiovascular and metabolic disorders)(6). Approximately 75% of isolated ACC cases have normal nerve growth, but it is not the case in ACC with other syndromes(8). ACC with other syndromes has more severe clinical symptoms, while isolated ACCs have mild symptoms(9).

Case presentation:

A girl was born at 35th week of pregnancy by cesarean section because of rupturing of membrane (ROM) from a 34-year-old mother in Motahari Hospital, Jahrom, Iran. Regarding the prenatal medical ultrasound in the 30th week, which was reported from the partial agenesis of corpus callosum, and according to the condition of the mother, who had ROM, cesarean section was performed and the neonate was hospitalized at NICU because of low Apgar at birth. The mother had no history of illness during pregnancy, and did not use special medication or alcohol. Parents' marriage was intra-familial and no genetic disease was reported in the baby's family. The birth weight of the infant was 1590 g (5% Percentile), the head circumference was 32 cm (5% Percentile) and its length was 40 cm (5% Percentile). The baby was born with Apgar score 4 and had an Apgar score 7 after five minutes. The baby received O₂ for one minute due to 80% O₂ saturation at birth until it reached 96% saturation. The neonate was Hyporeflex and had difficulty breathing. The baby had micrognathia and low set ears in terms of physical examination. Simian line was observed in the hands and the baby had hands deformity. The feet were clubbed (image2). dilatation of lateral ventricle and third ventricle as well as moderate hydrocephaly had been seen in the brain ultrasound. Subdural effusion was reported in the brain ultrasound. Brain CT scan was performed for further action on the second day of admission according to the grade IV intraventricular hemorrhage and severe atrophy of the brain

reported(image1). The baby died on the 6th day postnatal.

Discussion:

Corpus callosum is a forebrain commissure that originates from the early Lamina terminalis(10). Corpus callosum, as the largest nerve in the nervous system, is a collection of neural pathways that can function independently and connect different spaces of the brain. Imperfection in cell proliferation and migration, defect in the axon growth and glial growth causes incomplete formation or absence of formation. These events lead to various abnormalities(11, 12). We can mention Chiari II & I malformation, Migration Disorders, pachygyria, polymicrogyria, schizencephaly, Encephalocoles and Degenerative Disorders as examples of such abnormalities(13, 14).

Grade IV Intraventricular hemorrhage and severe brain atrophy were highlighted in the newborn baby in the current study. Intraventricular hemorrhage (IVH) is one of the most important complications of preterm infant births. One of the mechanisms responsible for IVH is a disruption of the cerebral blood flow. Disturbances in cerebral blood flow are associated with the development of IVH(15). The cerebral blood flow harmoniously fluctuates between the two hemispheres of the brain. This coordination shows the neural connections between the brain regions. The synchronization of blood flow changes is done operatively by corpus callosum(16). It seems that in cases of corpus callosum agenesis, which is a defect in the evolution and function of this part, it can justify the

problems due to its inadequate functioning as a defect in the coordination of blood flow fluctuations in the cerebral hemispheres. As a result, this disorder increases the likelihood of IVH occurrence. Another justification for this issue is that the lateral ventricles are widely separated in the agenesis of the corpus callosum(17). In the ACC disease, the two lateral ventricles are separated, and the third ventricle may occasionally be moved upward. In most cases, there is a persistent dilatation of the atria and occipital horns(18).

In similar cases of corpus callosum agenesis the third ventricle and the Monroe canal had enlarged in autopsy examinations and the ventricular system was dilated(19). Brain parenchyma involvement was also observed in intraventricular hemorrhage and dilatation of the ventricles(20). In two other ACC cases, cortical dilation with necrosis in cerebral parenchyma and deep gray nuclei bilaterally hemorrhage have been reported(21), which is similar to the case presented in this study. In the clinical case provided by Sheila et al., the preterm infant afflicted with agenesis corpus callosum and hypoplasia of the cerebellum vermis and lateral ventricles. Like the present case, the baby also did not have any reflexes and had deformities in her hand. However, the baby grew up to age 2 and was receiving rehabilitation interventions(22). But the newborn baby in the present study died on the 6th day. Similar to the case presented in the current study, in another case, which was a baby that died after 4 hours of cesarean section, the third ventricle was in a misplaced position and was dilated. The lateral ventricles were also slightly

dilated(23). In another case of ACC, the posterior horns of the lateral ventricles were dilated. Unlike previous cases, however, this case was detected at age eight and had managed to successfully survive infancy and childhood(14). But corpus callosum agenesis does not always cause severe brain problems. Unlike the present case, a girl with a full-fledged corpus callosum Agensis had no particular problem in her development until school age and she noticed her learning and communication problems when she turned 8 years old(24).

According to a study in preterm neonates with ACC, the volume of the brain decreases. This decrease is by far more than the reduction in the gray matter of the amygdala nuclei and the hippocampus(25).

The clubfeet was another symptom in the patient. In other cases, we have seen the incidence of this complication and ACC. In a study by Shkalim et al., Clubfeet was reported in three infants with ACC. Neonatal reflexes had reduced in two of these three neonates(26). The low set ears that that was highlighted in our case also represent a symptom that occurs in infants with ACC(27, 28).

Conclusion

In this study, we observed corpus callosum agenesis, which is associated with various abnormalities in the face, hands, legs and skull. The results of CT scan studies highlighted the incidence of IVH and brain atrophy. We propose that congenital defects of the corpus callosum seem to interfere with the coordination of blood flow circulation between the hemispheres,

resulting in IVH and subsequent brain atrophy.

References:

1. Heide, S., et al., Clinical, chromosomal and molecular characterization of a cohort of 273 patients with agenesis of the corpus callosum. *European Journal of Paediatric Neurology*, 2017. 21: p. e84. .
2. Paul, L.K., et al., Agenesis of the corpus callosum: genetic, developmental and functional aspects of connectivity. *Nature Reviews Neuroscience*, 2007. 8(4): p. 287. .
3. Adré J. du Plessis, Joseph J. Volpe, Chapter 2 - Prosencephalic Development, Editor(s): Joseph J. Volpe, Terrie E. Inder, Basil T. Darras, Linda S. de Vries, Adré J. du Plessis, Jeffrey J. Neil, Jeffrey M. Perlman, Volpe's Neurology of the Newborn (Sixth Edition), Elsevier, 2018, Pages 34-57.
4. Volpe, P., et al., Corpus Callosum and Septum Pellucidum Anomalies, in *Obstetric Imaging: Fetal Diagnosis and Care* (Second Edition). 2018, Elsevier. p. 162-172. e1.
5. de Villemeur, T.B., et al., Corpus callosum agenesis with clinically normal people caused by DCC mutations. Prenatal implication. *European Journal of Paediatric Neurology*, 2017. 21: p. e43.
6. Lieb, J. and F. Ahlhelm, Agenesis of the corpus callosum. *Der Radiologe*, 2018.
7. des Portes, V., et al., Outcome of isolated agenesis of the corpus callosum: A population-based prospective study. *European Journal of Paediatric Neurology*, 2018. 22(1): p. 82-92.
8. Kim, S.E., et al., Clinical outcomes and neurodevelopmental outcome of prenatally diagnosed agenesis of corpus callosum in single center of Korea. *Obstetrics & gynecology science*, 2017. 60(1): p. 8-17. .
9. Romaniello, R., et al., Clinical characterization, genetics, and long-term follow-up of a large cohort of patients with agenesis of the corpus callosum. *Journal of child neurology*, 2017. 32(1): p. 60-71. .
10. Chacko, A., R. Koul, and D.K. Sankhla, Corpus callosum agenesis. *Neuroscience*, 2001. 6: p. 63-66. .
11. Albright, J.P., Effect of Playbased Music Therapy on the Motor and Communication Skills with a Child with Partial Agenesis of the Corpus Callosum. 2011.
12. Bloom, J.S. and G.W. Hynd, The role of the corpus callosum in interhemispheric transfer of information: excitation or inhibition? *Neuropsychology review*, 2005. 15(2): p. 59-71.
13. Barkovich, A.J. and D. Norman, Anomalies of the corpus callosum: correlation with further anomalies of the brain. *American Journal of Roentgenology*, 1988. 151(1): p. 171-179.
14. Mohanty, C., et al., Sturge-Weber Syndrome with Corpus Callosum Agenesis- A Case Report. *Journal of Anatomical Society of India*, 2011. 60(2): p. 239-241.
15. Ballabh, P., Intraventricular hemorrhage in premature infants: mechanism of disease. *Pediatric research*, 2010. 67(1): p. 1. .
16. Quigley, M., et al., Role of the corpus callosum in functional connectivity.

American journal of neuroradiology, 2003. 24(2): p. 208-212. .

17. Singh, S. and S. Garge, Agenesis of the corpus callosum. *Journal of pediatric neurosciences*, 2010. 5(1): p. 83.

18. Romero, R. and R. Romero, Prenatal diagnosis of congenital anomalies. 1988.

19. LOSSER, J.D. and E.C. ALVORD JR, Agenesis of the corpus callosum. *Brain*, 1968. 91(3): p. 553-570. .

20. Bhat, V. and V. Bhat, Neonatal neurosonography: A pictorial essay. *The Indian journal of radiology & imaging*, 2014. 24(4): p. 389.

21. Tang, P., et al., Agenesis of the corpus callosum: an MR imaging analysis of associated abnormalities in the fetus. *American Journal of Neuroradiology*, 2009. 30(2): p. 257-263.

22. da Silva Pacheco, S.C., et al., Pediatric neurofunctional intervention in agenesis of the corpus callosum: a case report. *Revista Paulista de Pediatria (English Edition)*, 2014. 32(3): p. 252-256. .

23. Desai, A., A. Bhide, and S. Bhalerao, Agenesis of corpus callosum-a rare case. *Journal of postgraduate medicine*, 1999. 45(1): p. 20. .

24. Chiappedi, M., A. Fresca, and I.M.C. Baschenis, Complete Corpus Callosum Agenesis: Can It Be Mild? *Case Reports in Pediatrics*, 2012. 2012: p. 4.

25. Peterson, B.S., et al., Regional brain volume abnormalities and long-term cognitive outcome in preterm infants. *Jama*, 2000. 284(15): p. 1939-1947. .

26. Shkalim, V., et al., Three sibs with microcephaly, clubfeet and agenesis of corpus callosum: A new genetic syndrome? *American Journal of Medical Genetics Part A*, 2011. 155(5): p. 1060-1065. .

27. Graham, J.M., Jr., et al., A new X-linked syndrome with agenesis of the corpus callosum, mental retardation, coloboma, micrognathia, and a mutation in the Alpha 4 gene at Xq13. *Am J Med Genet A*, 2003. 123a(1): p. 37-44.

28. Shawky, R.M. and R. Gamal, C syndrome with skeletal anomalies, mental retardation, eyelid chalazion, Bitot's spots and agenesis of the corpus callosum in an Egyptian child. *Egyptian Journal of Medical Human Genetics*, 2017. 18(1): p. 93-97.

Tables and Charts:

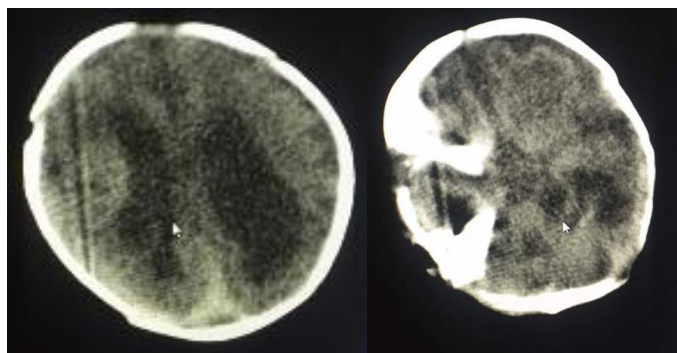


Figure 1: Brain CT scan on the second day (grade IV intraventricular hemorrhage and severe atrophy of the brain).

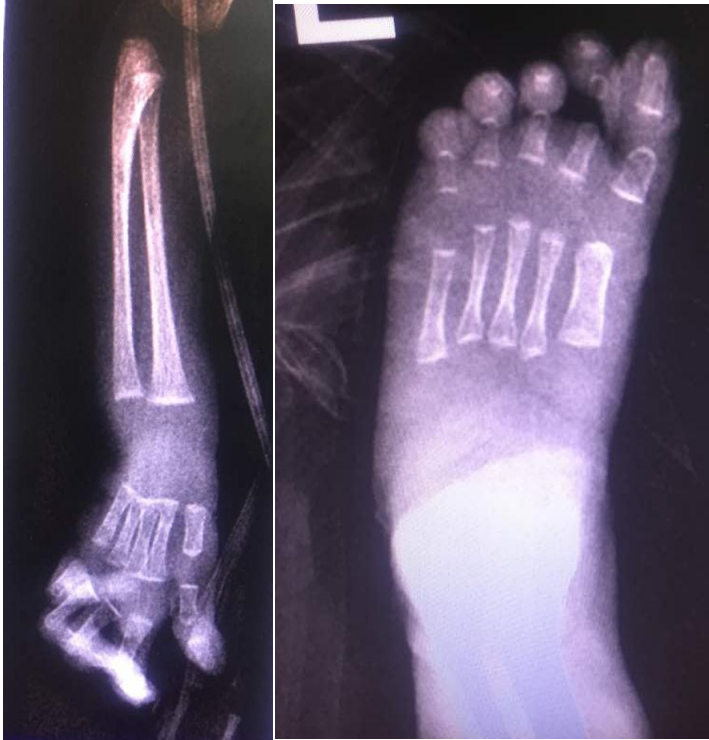

Figure 2: Radiography of foot and hand. Left (deformed hand). Right (club foot).