

Case Report

Spontaneous Union of Femoral Neck Stress Fracture without Surgery

Shadi Shayesteh Azar 1, Shayan Amjadi 2*, Mohammad Osia 1, Fatemeh Mohammadnejad 3,
Hamed Jafarpour 1

1. Student Research Committee, Mazandaran University Of Medical Science, Sari, Iran.
2. Orthopedic Resident, Orthopedic Research Center, Mazandaran University Of Medical Science, Sari, Iran
3. MSC Of Psychology, Orthopedic Research Center, Mazandaran University Of Medical Science, Sari, Iran.

*Corresponding Author: **Shayan Amjadi**, Orthopedic Resident, Orthopedic Research center, Mazandaran University of medical science, Sari, Iran. Email: shayanamjadi@yahoo.com

Abstract

Femoral neck fractures are serious injuries that are associated with high mortality and morbidity. Considerable controversy still exists for best treatment of non-displaced (Garden I and Garden II) fractures. Our case is a 34-year-old woman with Garden type II femoral neck fracture, who refused all surgical options and willingly ignored her problem. The patient received subcutaneous injections of 20 mcg Teriparatide for 6 weeks. 3 months later she returned to our center with uneventful recovery of her fracture. Although rigid internal fixation of femoral neck fractures has long been the cornerstone of treatment, especially in non-impacted cases, non-operative management does not mean a poor result.

Key words: Femoral Neck Fracture; Stress Fracture; Non-Displaced Fracture; Non-Operative Treatment

Introduction:

Femoral neck fractures are associated with high mortality and morbidity. Annual incidence is approximately 1.7 million (1, 2). The incidence has increased since the 1960s and is expected to double by year 2050 (1). In the US, 250,000 fractures happen each year (2-4). In the USA the annual cost has estimated to be nearly \$10 billion (1, 2, 5). There is a challenge against orthopedic surgeons to find the cheapest and most effective way to treat them. For non-displaced Garden I and Garden II, the traditional approach is rigid internal fixation with cannulated screws but Considerable controversy still exists for best treatment of non-displaced (Garden I and Garden II) fractures. In the following, a patient with a

femoral neck fracture without displacement, which is treated without a surgical procedure, is introduced.

Case presentation:

A 34-year-old woman presented with right side of hip pain since 3 weeks ago to the orthopedic clinic of imam hospital in sari. She had no history of trauma, but she had hypothyroidism for 8 years. She had a special diet for weight loss and jogging schedule from 6 months ago. The tenderness was evident in the proximal thigh. Hip joint range of motion was reduced. Radiography of the right hip showed non displaced femoral surgical neck fracture (garden Type II classification) (figure 1). Pelvic spiral CT-scan showed non displaced linear fracture at base of right femoral neck (figure 2). Pelvic

MRI showed linear abnormal signal with peripheral bone marrow edema and bruising in the medial aspect of the right femoral neck is suggestive for stress fracture also mild amount of effusion in the right hip joint and mild soft tissue edema at the anterior and posterior aspect of right femoral neck was shown (figure 3). The patient was advised to go through internal fixation but she declined this plan. The patient received subcutaneous injections of 20 mcg Teriparatide (CINNOPAR) for 6 weeks. Pelvic spiral CT-scan after 1 month showed no healing (Figure 4). She came back to the orthopedic clinic about 3 months later without any pain or limitation of motion .bone healing was confirmed in hip spiral CT scan (Figure 5). She described her treatment as 1 month of complete bed rest and the unrestricted but cautious activity afterwards .The patient gave informed consent prior to being included into the study.

Discussion:

Femoral neck fractures are one of the important health problems of human societies. The frequency of this “sickness of the aged” will increase enormously in the wealthy parts of the world, where the number of old people is growing very rapidly (1). The global incidence of hip fractures was estimated to be 1.6 million in 1990. This figure is expected to rise to 4 million in 2025 and to 6.3 million in 2050 per year (2). In the UK, the mortality following a femoral neck fracture is between 20% and 35% within 1 year in patients, of which 80% were women (2). Falls are the main reason for fracture in the elderly and high energy trauma is the major cause in younger patients (2).

Garden I is an incomplete fracture in which the line of fracture does not reach to the medial cortex and the head stays in relative valgus, while Garden II refers to all those complete but undisplaced fractures. In Garden III and IV there is complete and incomplete displacement, respectively (6). Displaced fractures of the femoral neck are necessarily treated through open reduction and internal fixation with cannulated screws or sliding hip screws or hip arthroplasty, depending on the age of the patients (2, 7, 8). For non-displaced Garden I and Garden II, the traditional approach is rigid internal fixation with cannulated screws through open or percutaneous approaches on the grounds of high probability of secondary displacement (7, 8). Various studies have been published on non-surgical treatment, in which most conservative treatments cause complete union of type 1 and 2 fractures (9-11). In a study by Shuqiang et al. Who reviewed the results of non-surgical treatment for pelvic fractures, 115 patients with Grade 1 and 2 were examined. 67 patients recovered without malunion and 48 patients needed surgery. The mean age of healed subjects was 62 years. In this study, the success of conservative treatment was determined by the morbidity and age of the patient, and surgical treatment was proposed for patients aged 60-80 years (9). Raaymakers et al. reported the need for secondary surgery intervention in 41% of patients over the age of 70 and in 7% of healthy subjects under 70 years of age (10). Otremski et al. reported secondary surgery in 2% of patients under the age of 68 years (11). Shayesteh Azar et al. at case report, in 2012, introduced a 46-year-old woman with non-displaced garden type II

femoral neck fracture in which recovered spontaneously after 6 months (1). In present case radiologic and clinical healing was seen after 3 months

adnan et al in a prospective study evaluated 170 patients with non-surgical treatment by weight-bearing restriction and immobilization, which 86% of patients improved (12). The difference between the present case and the studies was that of administering Teriparatide (cinnopar) and age of the patient, which was not studied in other studies.

Contradictory recommendations for non-surgical treatments are available in various studies. From the point of view of medical ethics, it is difficult to design a method for checking the accuracy of non-surgical treatment. Although various clinical studies have been conducted for non-surgical treatments, many of them were retrospective and there was no matching between the studied groups. In prospective studies that have been considered non-surgical treatment for grade 1 and 2, there is no clear indication of the precise validity of this treatment and is still considered as a recommendation to reduce the complications of surgery. The high level of controversy about the exact rate of secondary displacement as the basic rationale of operative treatment is unclear.

Conclusions:

Although rigid internal fixation of femoral neck fractures has long been the cornerstone of treatment, especially in non-impacted cases, non-operative management does not mean a poor result.

References:

1. Azar MS, Saravi MS, Kariminasab MH, Taghipour M, Sharifian R. Complete spontaneous improvement of non-displaced femoral neck fracture without any surgery modality. *The American journal of case reports*. 2012;13:22.
2. Raaymakers E. Fractures of the Femoral Neck. A Review and Personal Statement. *Acta chirurgiae orthopaedicae et traumatologiae Cechoslovaca*. 2006;73(1):45.
3. Gebhard JS, Amstutz HC, Zinar DM, Dorey FJ. A comparison of total hip arthroplasty and hemiarthroplasty for treatment of acute fracture of the femoral neck. *Clinical orthopaedics and related research*. 1992(282):123-31.
4. Karamy A, Akbarzadeh M, Shamsoddini A, Moghtadaei M, Zangi M, Akbariyan E. Post-treatment Complications after Femoral Neck Fractures using Internal Fixation Method. *Ann Mil Health Sci Res*. 2009;6(4):225-31.
5. Rogmark C, Carlsson Å, Johnell O, Sernbo I. Costs of internal fixation and arthroplasty for displaced femoral neck fractures. *Acta Orthopaedica Scandinavica*. 2003;74(3):293-8.
6. Motififard M, Teimouri M, Mollabashi M, Soleimani E. Displaced Femoral Neck Fracture in Elderly Patients: Comparison of Primary Total Hip Arthroplasty with Internal Fixation. *Journal of Isfahan Medical School*. 2010;28(111).
7. Cabanela ME. Femoral neck fractures: to pin or not. *Orthopedics*. 1999;22(9):833-4.
8. Bartels S, Gjertsen J-E, Frihagen F, Rogmark C, Utvåg SE. High failure rate after internal fixation and beneficial outcome after

arthroplasty in treatment of displaced femoral neck fractures in patients between 55 and 70 years: An observational study of 2,713 patients reported to the Norwegian Hip Fracture Register. *Acta orthopaedica*. 2018;89(1):53-8.

.⁹ Shuqiang M, Kunzheng W, Zhichao T, Mingyu Z, Wei W. Outcome of non-operative management in Garden I femoral neck fractures. *Injury*. 2006;37(10):974-8.

.¹⁰ Raaymakers E. The non-operative treatment of impacted femoral neck fractures. *Injury*. 2002;33:8-14.

.¹¹ Otremski I, Katz A, Dekel S, Salama R, Newman R. Natural history of impacted subcapital femoral fractures and its relevance to treatment options. *Injury*. 1990;21(6):379-81.

.¹² Faraj AA. Non-operative treatment of elderly patients with femoral neck fracture. *Acta orthopaedica Belgica*. 2008;74(5):627-9.

Figures:

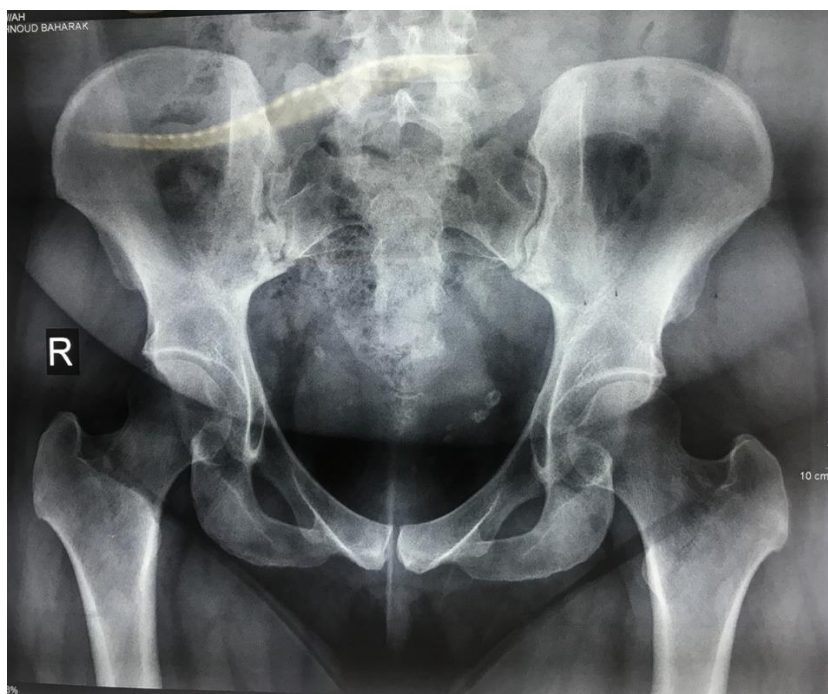


Figure 1: non displaced femoral surgical neck fracture on pelvic x-ray

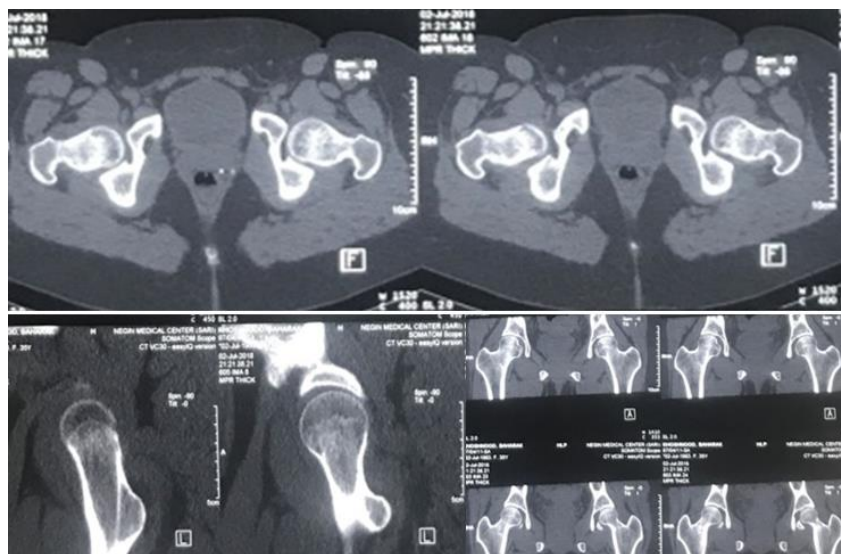

Figure 2: Pelvic spiral CT-scan showed non displaced linear fracture at base of right femoral neck

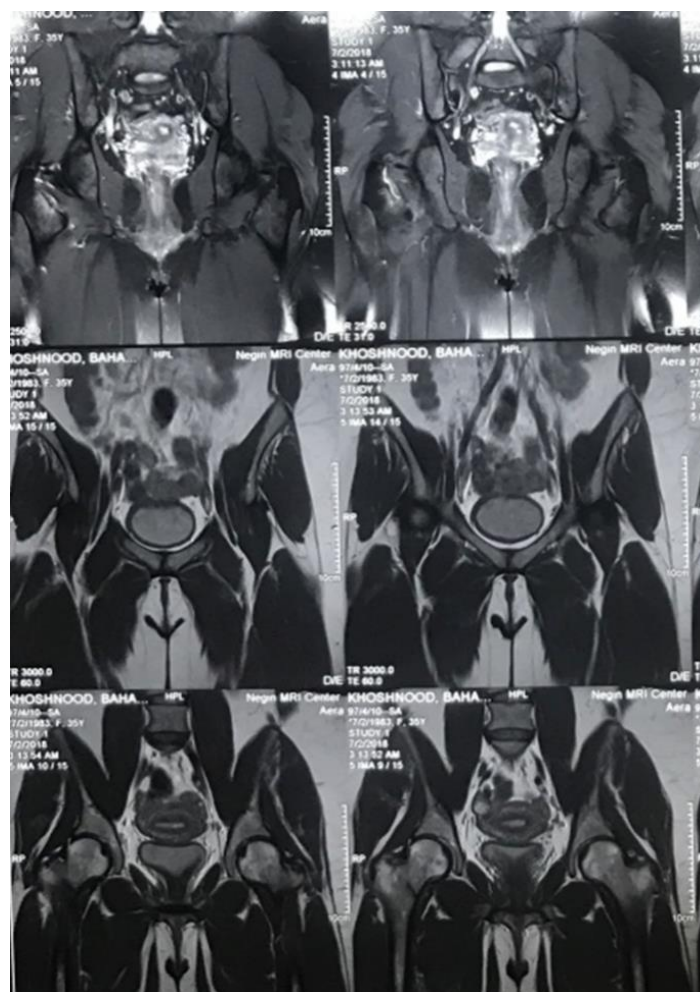


Figure 3: Pelvic MRI showed a stress fracture at right femoral neck

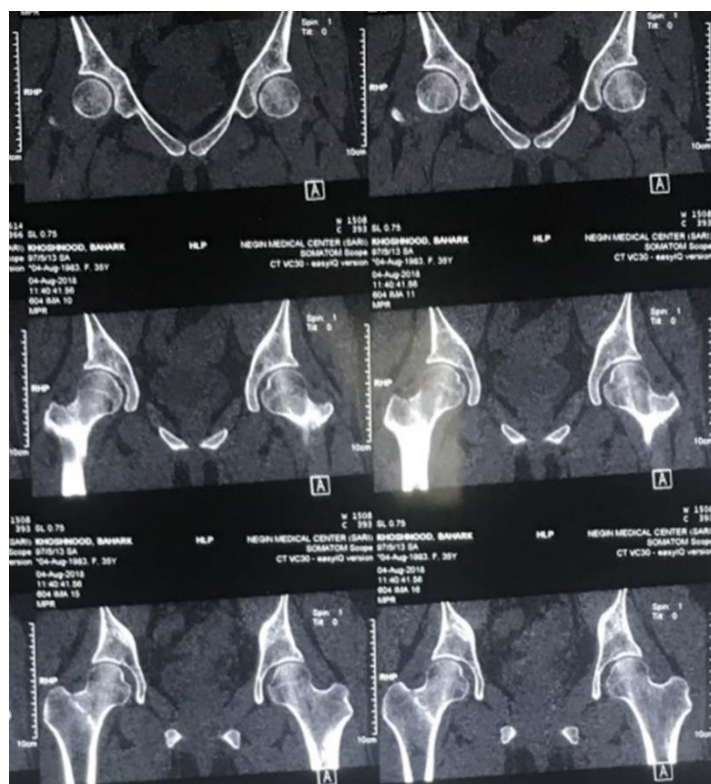


Figure 4: spiral CT scan after 1 month showed no healing

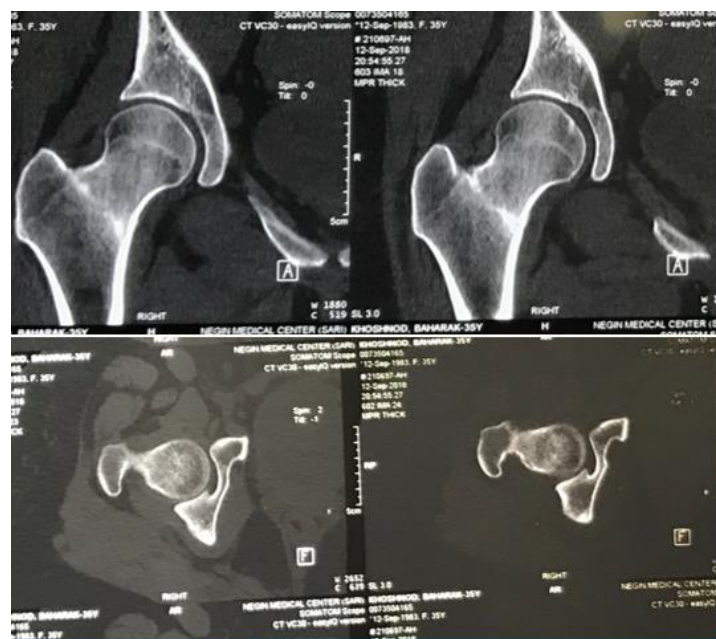


Figure 5: hip spiral CT scan after 3 months showed complete healing