

Case Report

Acquired Urethral Diverticula after Long-Term Cycling, A Case Report

Mohammad Jabbari¹, Morteza Fallah karkan^{2*}

1. Fellowship of reconstructive urology, Shohada –e- Tajrish Hospital, Shahid Beheshti University of Medical Sciences, Tehran, Iran.
2. Urology resident, Shohada –e- Tajrish Hospital, Shahid Beheshti University of Medical Sciences, Tehran, Iran

*Corresponding Author: **Morteza Fallah karkan**, Urology resident Shohada –e- Tajrish Hospital, Shahid Beheshti University of Medical Sciences, Tehran, Iran. Email: Mortezafallah.md@gmail.com

Abstract

Urethral diverticula are rare in males and most are acquired. Herein we are reporting a young boy with history of two years professional cycling and complained about urinary incontinency especially during cycling and, post-void dribbling successfully managed by surgical excision of bulbar urethra diverticulum.

Keywords: Urethral diverticulae, Urinary incontinence, Post void dribbling Male, Cycling

Introduction:

Urethral diverticula (UD) are rare clinical entities in males with a peak age incidence of 25 to 45 years and most are acquired (1) usually occur at the penoscrotal junction or bulbous urethra (2, 3). Patients may presents with recurrent Urinary Tract Infections (UTI), incontinence, pelvic pain, post-void dribbling, dysuria, urgency and frequency (1). A perineal mass or swelling at the penoscrotal junction may occur and urethrocutaneous fistula may develop if infected (4). Herein we are reporting a young boy with history of two years professional cycling and complained about urinary incontinency especially during cycling and, post-void dribbling. The present report is involved with human participant, who signed the informed consent.

Case Presentation:

A 17-year-old male with no specific pathological history presented to the urology department, having complain of post void dribbling and incontinence of urine which initially started for a year before and gradually increased in severity over the past 3 months. No abnormality seen on physical examination. Blood and urine investigations revealed in normal range. He mentioned that he has started professional cycling since two years ago. A simultaneous voiding cystourethrogram and retrograde urethrogram showed a large diverticulum in bulbous urethra, no stricture seen in other parts of urethra (Figure 1-A). Patients were placed in exaggerated lithotomy under spinal anaesthesia. A 0° optic 17 Fr cystoscope was passed and only demonstrated a pinpoint ostium located on the bulbar urethra at 6 o'

clock which was hard to find it and inserted a guide wire through it into the diverticula. The affected segment of bulbous urethra was completely excised (Figure 1-B) and primary repair was performed longitudinally over a transurethral 16 French silicone catheter. A layer of tunica vaginalis and penile dartos was interposed to avoid fistula. Postoperative recovery was uneventful. The Pathologic examination reported stromal chronic inflammatory accompanied by fibrosis and granulation tissue. Three weeks later the pericatheter retrograde urethrogram showed a normal urethra (Figure 2) and the catheter was removed. The patient voided normally after the removal of the catheter and is doing well at 6 months of follow-up.

Discussion:

UD is an out-pouching of the urethral wall and having a free communication with the urethral lumen (4). Acquired UD's often result from blunt trauma, stricture, infection and surgical implants erosion into the urethral lumen (5, 6). UD have also been recognized as a complication resulting after hypospadias or urethral stricture repair (7) and transurethral prostate or bladder procedures (5). The communication between the UD and the urethral lumen may have a narrow (like our case) or a wide neck (5). Suspected etiopathogenic theories for acquired male UD is; the first mechanism is related to obstruction and increased urethral pressure upstream of an obstruction which leads to herniation of the urethral epithelium. The second mechanism is a result of constant pressure distributed on the penoscrotal angle, which causes chronic urethral ischemia and finally the formation of scars. The main

pathology finding in our patient due to professional cycling nearly 140 kilometer per week. The third mechanism incorporates anorectal malformation repair with UD. Another mechanism is rupture of the periurethral glands into the urethral lumen secondary to obstruction that could generate epithelization and the forming periurethral cavity. Also UD can develop secondary to suppuration and necrosis of urethral wall following trauma, endourethral manipulation and drainage of a prostatic or periurethral abscess (3, 4, 8). The diagnosis of male UD depends on a detailed history-taking and radiologic studies, including retrograde urethrography and voiding cystourethrography (2). While many patients who present with symptoms related to the UD require surgical correction. Consideration should be given to symptoms, the size and thickness of the UD wall, integrity of the corpus spongiosum and concomitant urethral pathology (5, 8). Uncomplicated asymptomatic UD can be managed watchful waiting provided the patient commits to regular follow-up (5). The recommended treatment for complicated symptomatic UD is surgical excision of diverticulum and urethral reconstruction, maintain the patency and unity of urethra and an additional tissue cover if required (3, 9, 10). In our case, due to the urinary symptoms, a surgical management was decided. On follow up after 6 months the patient had no urinary symptoms.

Conclusion:

In this paper, we described a young male individuals presenting with a large UD of the bulbar urethra. The possible

aetiopathogenesis for the diverticulum, in this case, may be caused by prolonged cycling as a result of constant pressure distributed on the penoscrotal and prineal region which causes chronic urethral ischemia and induces urethral fibrosis and scar formation.

Conflict of Interest:

None declared.

References:

1. El Ammari JE, Riyach O, Ahsaini M, Ahallal Y, El Fassi MJ, Farih MH. Acquired urethral diverticulum in a man with paraplegia presenting with a scrotal mass: a case report. *Journal of medical case reports*. 2012;6(1):392.
2. Li X, Sa Y, Jin C, Xu Y. Traumatic urethral diverticula: a rare malformation of the male urethra. *Urologia internationalis*. 2013;90(4):484-6.
3. Thakur N, Sabale VP, Mane D, Mulla A. Male urethral diverticulum uncommon entity: Our experience. *Urology annals*. 2016;8(4):478.
4. Kamal MR, Jindal T, Sinha RK, Karmakar D. Congenital giant male anterior urethral diverticulum with calculi. *BMJ case reports*. 2014;2014:bcr2013202831.
5. Cinman NM, McAninch JW, Glass AS, Zaid UB, Breyer BN. Acquired male urethral diverticula: Presentation, diagnosis and management. *The Journal of urology*. 2012;188(4):1204-8.
6. Mirzazadeh M, Fallah-karkan M, Hosseini J. Penile fracture epidemiology, diagnosis and management in Iran: a narrative review. *Translational andrology and urology*. 2017;6(2):158.
7. Alphs HH, Meeks JJ, Casey JT, Gonzalez CM. Surgical reconstruction of the male urethral diverticulum. *Urology*. 2010;76(2):471-5.
8. Santos JC, Rolim N, Mota RL, Monteiro H. Acquired male urethral diverticulum: a rare entity treated in a one-stage procedure. *BMJ case reports*. 2016;2016:bcr2016216670.
9. Gandhi C, Inamdar P, Prasadi S, Kulkarni S. Urethral diverticulum with proximal urethral stricture: An unusual presentation. *Medical Journal of Dr DY Patil University*. 2013;6(4):426.
10. Razzaghi MR, Fallah-karkan M, Ghiasy S, Javanmard B. Laser Application in Iran Urology: A Narrative Review. *Journal of lasers in medical sciences*. 2018;9(1):1.

Figures:

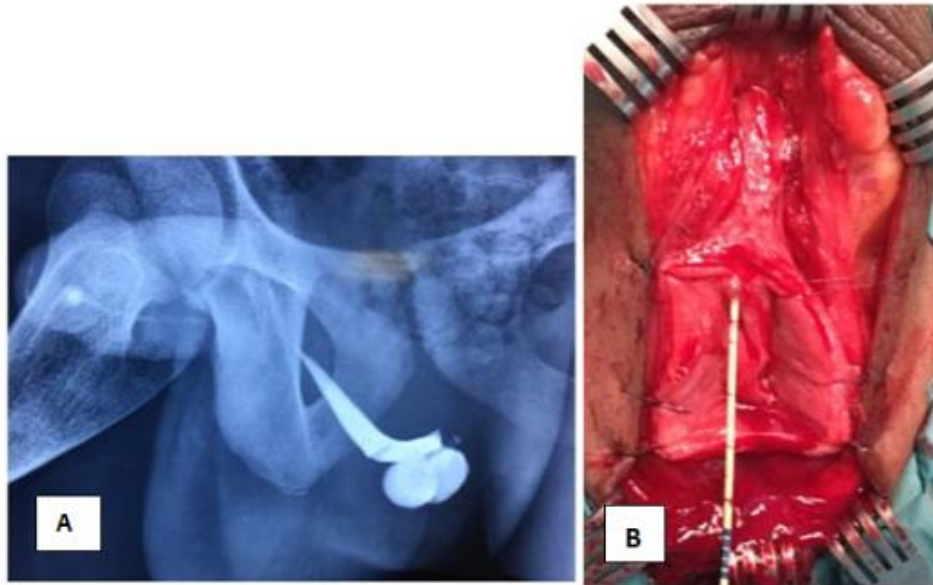


Figure 1: A) cystourethrogram showed a large diverticulum in bulbous urethra, B) Intraoperative images of the Perineal dissection showing the bulbar urethra already dissected

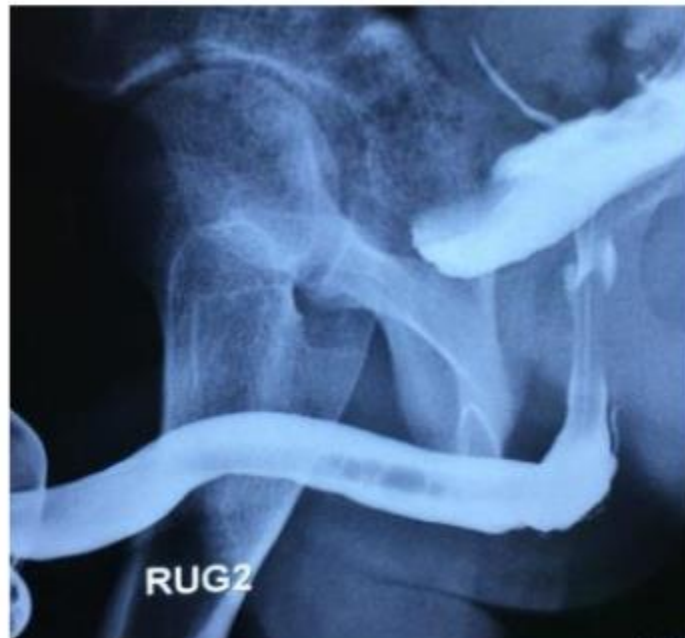

Figure 2: Postoperative pericatheter retrograde urethrogram showing a clearly defined urethra without any strictures or diverticulum.