

Case report

Soft Tissue Reconstruction for Chronic Peroneal Tendon Dislocation with Plantaris Tendon

Majid Sajjadi Saravi 1, Mohammad-Hossein Karimi-Nasab 2, Masood Shayesteh-Azar 3*,
Shayan Amjadi 4

1. Resident Of Family Medicine Department Of Family And Community Medicine University Of Toronto Southlake Regional Health Centre, Newmarket, Ontario.
2. Associate Professor Of Orthopedic Surgery, Mazandaran University Of Medical Science, Sari, Iran.
3. Associate Professor Of Orthopedic Surgery, Mazandara University Of Medical Science, Sari, Iran.
4. Orthopedic Resident, Orthopedic Research Center, Mazandaran University Of Medical Science, Sari, Iran.

*Corresponding Author: **Masood Shayesteh Azar**, Associate professor of orthopedic surgery, Orthopedic Research center, Mazandara University of medical science, Sari, Iran. Email: mshayestehazar@yahoo.com

Abstract:

Recurrent dislocation of peroneal tendons is a relatively rare ankle problem with numerous described surgical treatments which make the orthopaedic surgeons baffled in choosing the appropriate procedure. An 18 year old girl with a two years history of recurrent peroneal dislocation was treated successfully using plantaris tendon for delta-shape reconstruction of superior peroneal retinaculum. Her recovery was uneventful without any major complications or recurrence except surgical site tenderness and mild swelling for 5 months after surgery making a delta shaped retinaculum using plantaris tendon effectively prevents the dislocating peroneal tendons.

Keywords: Peroneal Tendons; Recurrent Dislocation; Plantaris Tendon

Introduction:

It is really amazing that so different and numerous operations have been described for a rare injury (1, 2). Although there is no precise statistics about its prevalence, our personal experience tells us that it must be very rare injury or a more common injury which is satisfactorily treated with conservative treatment offered mistakenly for ankle sprain.

The mechanism of injury is recognized as forceful dorsiflexion and rupture or evulsion of superior retinaculum and periosteum from lateral malleol (1,2). There is some controversy about the role of

peroneal groove depth and its variation in width, thickness and insertion pattern in susceptibility to this injury (3,4,5).

Considering the pathogenesis of this injury, reattachment of the superior peroneal retinaculum to the lateral malleol as described in many literature seems to be logical (5,6) however finding thick enough tissue to be sewn can be quite challenging, dictating searching for a soft tissue for substitution or abandoning soft tissue reconstruction in favor of bony procedures.

Case presentation:

An 18 year old girl with a two years history of recurrent peroneal dislocation was

selected for operation. Her problem started acutely with an episode of ankle torsion causing severe swelling on the lateral site of ankle. After subsidence of swelling, a full-blown case of recurrent peroneal tendon dislocation was established. She starts to experience snapping and passage of tendons over lateral maleole with every attempted eversion and dorsiflexion.

The operation started under general anesthesia with an 8 cm hockey stick incision centered over posterior border of lateral maleole. It was apparent after incision that both peroneal tendons are easily going back and forth while being covered with attenuated deep fascia. At this stage, with minimal dissection in the anteromedial aspect of Achilles tendon as B.H Hansen described in his valuable case report(6), plantaris tendon was found and released proximally from the same lateral approach. The 12 centimeter, distally attached plantaris graft was then led through the posterior border of lateral maleole about 5 cm proximal to its tip. In Contrast to the technique described by Hansen, we preferred to use two short tunnel dug from lateral border of posterior surface of lateral maleole to its lateral surface 1cm anterior to starting point. Plantaris tendon which was passed through the upper tunnel retrieved from the second one to be finally sutured to itself to make a delta-shaped retinaculum.

After completion of surgery, the operated foot was put in sort leg splint which was changed to fiberglass short leg cast two weeks later after suture removal.6 weeks after operation, the cast was removed and physical therapy started. We followed the patient for 18 months afterwards. Her recovery was uneventful without any major

complications or recurrence, but she complained of surgical site tenderness and mild swelling for 5 months after operation.

Discussions:

Recurrent dislocations should be managed surgically. Five basic categories of repair have been described: (i) anatomical reattachment of the retinaculum; (ii) bone-block procedures; (iii) reinforcement of the superior peroneal retinaculum with local tissue transfers; (iv) rerouting the tendons behind the calcaneofibular ligament; and (v) groove deepening procedures. However, it is impossible to determine from the relatively small series which procedure is superior (7).

Since the primary pathogenesis in recurrent peroneal dislocation is the defect in superior peroneal retinaculum and lack of its function in holding back the peroneal tendon against the smooth surface, it is rationally deductable that reconstruction of peroneal retinaculum with local available tissues would be appropriate. Posteriorly attached perosteal flap from lateral maleole turned over peroneal tendon was described by Zoellner and Clancy to fortify local tissue and to stop peroneal tendons from leaving their location (6) .However, preserving the pivot point of this delicate tissue seems very challenging.

Achilles tendon, peroneus brevis, proneustertius and plantaris have been used by various authors in reconstruction of superior retinaculum (8, 9). Achilles tendon with its strong distal insertion in the vicinity of pathologic site sounds appropriate to be used but the possibility of weakening it or inducing Achilles tendinitis is frightening (8). Usage of the plantaris tendon in soft tissue reconstruction of superior

retinaculum was first introduced in 1967 by Miller through three incisions (5). In a published case report in 1996, Henson modified the technique of Miller by operating through one incision (6). He described the process of cutting plantaris tendon proximally and passing it through a transverse tunnel through lateral malleol and suturing it back on itself. His description was so vivid and inspiring that we decided to choose his approach. Especially, we owe the process of finding plantaris tendon through lateral approach to Hensen. But, as we had thought of before operation, we needed more than on restrain for holding back the dislocating tendons.

Therefore, instead of making a single through and through tunnel, we managed to make a delta shaped retinaculum by passing the plantaris tendon through two short tunnels and suturing the tendon to itself which effectively prevents the dislocating peroneal tendons from moving forwards over lateral malleol or bowstringing superior or distal to one strand reconstructed retinaculum.

References:

- 1- Eckert WR, Davis JE. Acute rupture of the peroneal retinaculum. *The Journal of bone and joint surgery. American volume.* 1976;58(5):670-2.
- 2- Escalas FE, Figueras JM, Merino JA. Dislocation of the peroneal tendons. Long-term results of surgical treatment. *The Journal of bone and joint surgery. American volume.* 1980;62(3):451-3.
- 3- Zoellner G, Clancy JW. Recurrent dislocation of the peroneal tendon. *The Journal of bone and joint surgery. American volume.* 1979;61(2):292-4.
- 4- Larsen E, Flinck-Olsen M, Seerup K. Surgery for recurrent dislocation of the peroneal tendons. *Acta orthopaedica Scandinavica.* 1984;1;55(5):554-5.
- 5- Miller JW. Dislocation of peroneal tendons-A new operative procedure. A case report. *Am. J. Orthop.* 1967;9:136-7.
- 6- Hansen BH. Reconstruction of the peroneal retinaculum using the plantaris tendon: a case report. *Scandinavian journal of medicine & science in sports.* 1996;6(6):355-8.
- 7- Ferran NA, Oliva F, Maffulli N. Recurrent subluxation of the peroneal tendons. *Sports Medicine.* 2006 Oct 1;36(10):839-46.
- 8- Stein RE. Reconstruction of the superior peroneal retinaculum using a portion of the peroneus brevis tendon. A case report. *JBJS.* 1987;1;69(2):298-9.
- 9- Mick CA, Lynch F. Reconstruction of the peroneal retinaculum using the peroneus quartus. A case report. *JBJS.* 1987;1;69(2):296-7.

Figures:

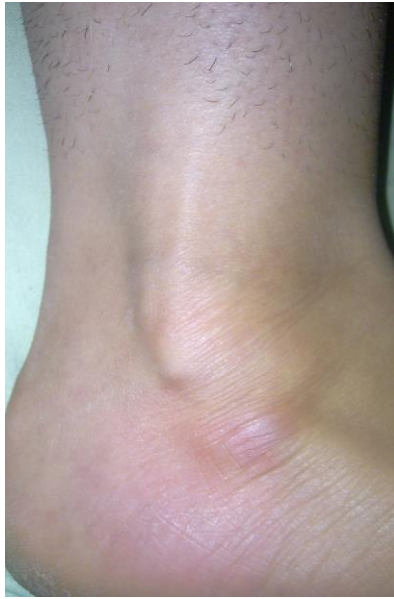

Figure 1: dislocated tendons can be seen before operation.

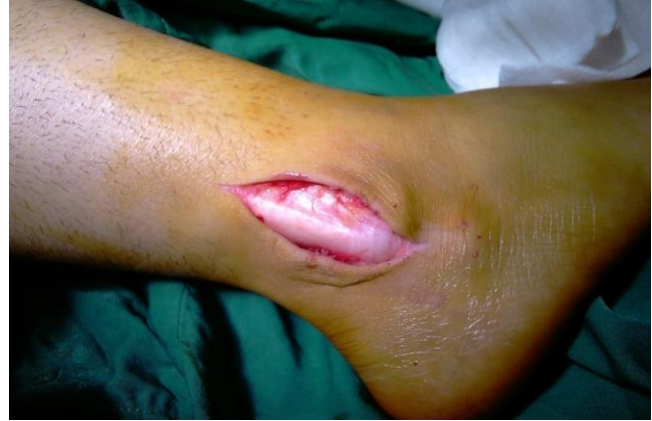

Figure 2: after incision. Peroneal tendons over lateral malleol, covered by deep fascia

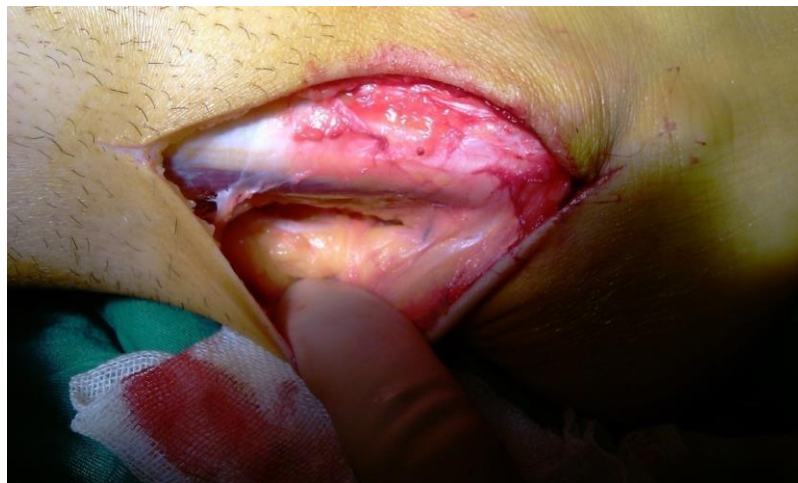

Figure 3: Finding the plantaris tendon on anteromedial aspect of Achilles tendon

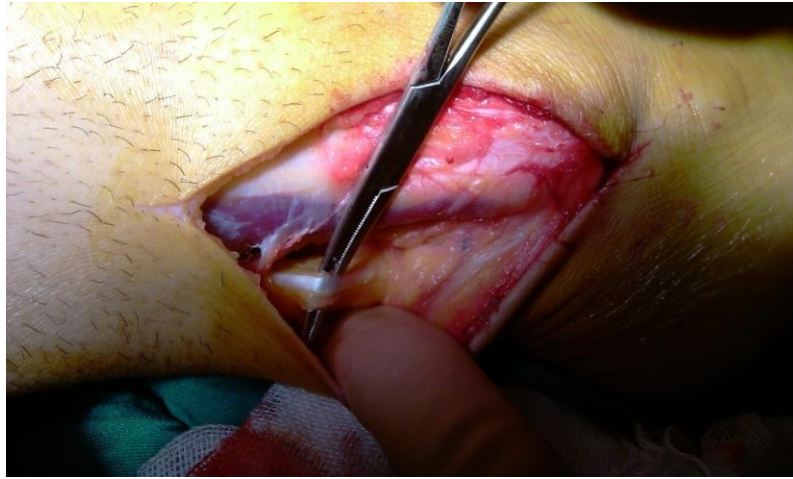


Figure 4: releasing the plantaris tendon

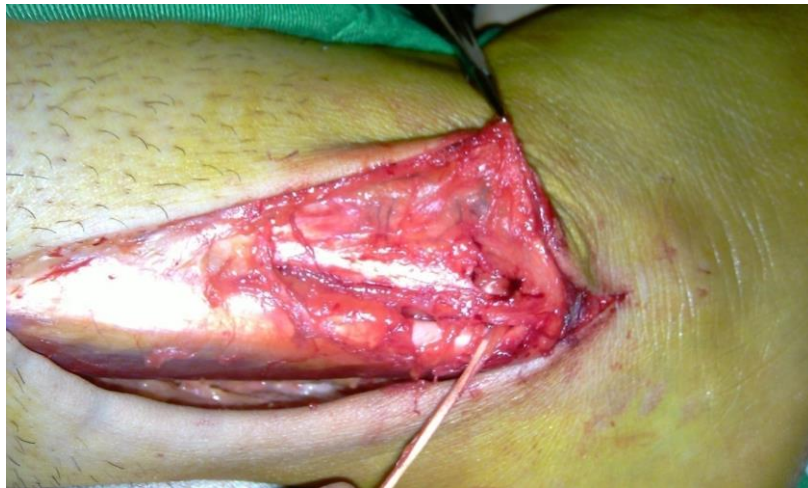

Figure 5: Plantaris tendon went through two tunnel and is ready to be sewn over itself

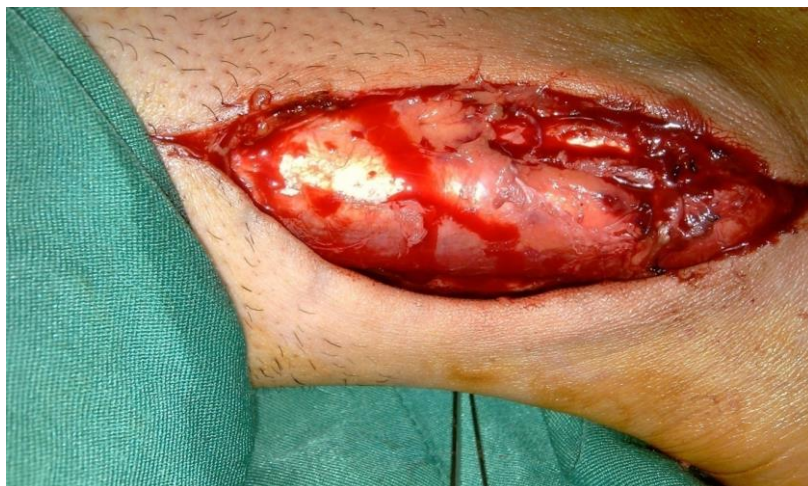

Figure 6: delta shaped reconstructed retinaculum prevents the peroneal tendons from being dislocated again