

Case Series

A Case Series of Portal Vein Thrombosis Following Laparoscopic Sleeve Gastrectomy

Omar Al-Shawabkeh MD 1 *, Ramadan Al-Hasanat MD 2, Adnan Zayadeen MD 3, Mohammed Al-Hroot MD 4, Wael Ali Al-Na'ssan MD 5 ,

1. Laparoscopic and Bariatric Surgery Specialist, Department of Surgery, Division of upper GI, laparoscopy and bariatric surgery , Royal Medical Services, Amman, Jordan.
2. Laparoscopic and Bariatric Surgery Specialist, Department of Surgery, Division of upper GI, laparoscopy and bariatric surgery, Royal Medical Services, Amman, Jordan.
3. Senior Specialist in Diagnostic Radiology, Radiology Department, Royal Medical Services, Amman, Jordan.
4. FACS, Laparoscopic and Bariatric Surgery Consultant, Department of Surgery, Division of upper GI, laparoscopy and bariatric surgery, Royal Medical Services, Amman, Jordan.
5. FACS, Laparoscopic and Bariatric Surgery Consultant, Department of Surgery, Division of upper GI, laparoscopy and bariatric surgery , Royal Medical Services, Amman, Jordan.

*Corresponding author: Omar Al-Shawabkeh

shawabkeh_omar@yahoo.com.

ABSTRACT

Background: laparoscopic sleeve gastrectomy is presently the most common bariatric surgery at our center (King Hussein Medical Center). Portal vein thrombosis is a rare surgical complication with an insidious presentation and a high risk of bowel compromise. The aim of this study is to present a series of patients who developed portal vein thrombosis post sleeve gastrectomy, and to describe the overall incidence, associated risk factors, clinical presentation and management.

Case Reports: Four patients developed portal vein thrombosis post laparoscopic sleeve gastrectomy at King Hussein Medical Center during the period (Jan 2006 to Feb 2017). All patients presented with abdominal pain, nausea, and vomiting and decrease oral intake. The abdominal Computed tomography (CT) scan confirmed the diagnosis of portal vein thrombosis in all of them. One patient required medical treatment along with operative intervention and bowel resection. The other three patients were treated conservatively with anticoagulation and fluid resuscitation.

Conclusion: Portal vein thrombosis is a rare but severe complication after laparoscopic bariatric surgery. Familiarity with this high-risk entity is critical. Early diagnosis and management, initiated by a high index of suspicion, is crucial.

Key Words: Acute Porto-mesenteric Venous Thrombosis, Laparoscopic Sleeve Gastrectomy.

Background

Portomesenteric vein thrombosis (PMVT) is a rare but potentially life threatening condition that may lead to intestinal

ischemia and infarction [1, 2]. It has been described to occur as a result of local causes such as: (liver cirrhosis, diverticulitis,

pancreatitis, cholecystitis, inflammatory bowel disease, {hepatocellular, gastric, pancreatic cancers}) or systemic causes like: (myeloproliferative disorders, pregnancy, and oral contraceptives) [3]. Postsurgical PMVT is most common after procedures including ligation of, manipulation of, or injury to the portomesenteric venous system, such as splenectomy, liver transplantation, and the use of portal systemic shunts [4-7]. PMVT has been found to occur after laparoscopic surgery as well despite the absence of direct manipulation of the portal or major mesenteric vessels [8]. Possible causative factors include; increased intraabdominal pressure with pneumoperitoneum results in decreased portal venous blood flow, which may lead to a relative prothrombotic environment [9, 10].

Patients undergoing bariatric surgery are at an increased risk for venous thromboembolism (VTE) due to the underlying inflammatory and hypercoagulable states and because metabolic syndrome may predispose patients to VTE [11, 12].

The laparoscopic sleeve gastrectomy (LSG) is becoming one of the most popular operations for the treatment of morbid obesity, due to its acceptable morbidity and long-term weight loss, as compared with the Roux-en-Y gastric bypass, [13–16] actually in our center it is the most common bariatric surgery being done during the period (2006-2017). We herein report on a single-center series of 4 patients who had developed PMVT after LSG, in which we describe the overall incidence, associated risk factors, clinical presentation and management of these cases.

During a literature search, we identified a limited number of case reports and series describing PMVT following laparoscopic

bariatric surgery as an uncommon complication.

CASE REPORTS

Of 655 patients who underwent laparoscopic sleeve gastrectomy for morbid obesity at our center during the period from 2006 to 2017, four patients developed acute PMVT in the early postoperative period. All of the four LSGs were performed within the same center; therefore, surgical team, operative technique, prophylactic antibiotic regimen and thromboembolism prophylaxis protocol were the same among all of them. After obtaining the approval from the Royal medical services ethical and research committee, data was obtained from the retrospectively review of the medical records of patients who underwent LSG in our center and developed PMVT post operatively.

Under general anesthesia, the patient was placed in reverse Trendelenburg lithotomic position, we performed 4 incisions; pneumoperitoneum was created using the open technique, with a maximum preset pressure of 15mmHg. A liver retractor was placed through a 5 mm incision in the epigastrium. The gastrosplenic ligament as well as gastrocolic omentum were divided using a vessel sealer and divider LigaSure Atlas®. A 40-Fr endoluminal endoscope was used to size the lumen. Gastric resection was performed using a gastrointestinal flexible endo-stapler [EndoGIA®]. Staple line reinforcement with continuous lambert suture was used in 2 patients while the other 2 patients had not. During dissection of the lesser sac and posterior stomach, the portomesenteric circulation was not visualized or manipulated. A 16-Fr redivac drain was placed along the staple line at the conclusion of the operation. The mean operation room time was 100 min (range 70–135 min).

All patients were given the subcutaneous low-molecular-weight heparin (LMWH) enoxaparin (Innohip®) at 4500 IU per day, initiated intra-operatively and continued till the discharge day. Also they all start walking within 4–6 h of surgery with assistance; intravenous fluid therapy was also administered. No complications were observed during hospitalization. All of the patients were discharged 48–72 h after surgery

Case 1

A 36-year-old female with a BMI of 49 kg/m², admitted for LSG. Her medical history included Diabetes and history of oral contraceptive pill use for 3 years. Her operation was uncomplicated; she had an uneventful postoperative course and was discharged from the hospital on the second postoperative day. On the 32th postoperative day, she developed constant and diffuse abdominal pain that progressed in severity over the following 3 days. On presentation at this time, she appeared dehydrated with mild distension and had moderate tenderness. She was suspected of having an anastomotic leak. However computerized tomography (CT) of the abdomen confirmed the diagnosis of portal vein thrombosis (Figure 1). Therefore, the patient was treated conservatively with anticoagulation therapy, initially started with heparin and thereafter shifted to warfarin, which was continued after discharge.

Case 2

A 41-year-old female patient with a body mass index of 48.2 kg/m² was admitted for LSG. The patient's past medical history included morbid obesity, hypertension and dyslipidemia. No history of oral contraceptive use or smoking. Her initial physical examination was unremarkable.

The patient underwent LSG and experienced some nausea and vomiting post-operatively, alleviated with antiemetics. She tolerated her bariatric full liquid diet and was discharged home two days later. After 14 days she began to have abdominal pain, nausea and vomiting. She presented to the emergency room with: low-grade fever, tachycardia and signs of dehydration. A CT scan revealed PMVT but no evidence of bowel or hepatic ischemia (Figure 2). Therefore, the patient was treated conservatively and was placed on intravenous heparin initially and thereafter shifted to oral warfarin, which was continued for 6 months after discharge.

Case 3

A 54-year-old man presented as an emergency with diffuse abdominal pain, nausea, and vomiting. The body mass index (BMI) of the patient was 42 kg/m². He was smoker (one pack/day). He had undergone LSG 21 days prior to the index admission. The laboratory findings were insignificant, with only an increase in white cell count. Computerized tomography (CT) of the abdomen confirmed the diagnosis of portal vein thrombosis (Figure 3,4,5,6,7,8). He was admitted to the hospital, dehydrated, and was started on medical treatment with intravenous heparin infusion, fluid resuscitation. Thereafter he was shifted to warfarin, which was continued after discharge.

Case 4

A 44-year-old man presented as an emergency with diffuse severe abdominal pain, low-grade fever, nausea, and vomiting with history of decrease oral intake. The body mass index (BMI) of the patient was 47 kg/m². He had undergone an uneventful laparoscopic sleeve gastrectomy for the treatment of morbid obesity 18 days prior to the index admission. The laboratory findings

were within normal levels, with only a mild increase in white cell count. Computerized tomography (CT) of the abdomen confirmed the diagnosis of portal vein thrombosis (Figure 9,10,11,12). Therefore the patient was immediately treated with therapeutic infusion of heparin and broad spectrum antibiotics along with aggressive fluid resuscitation, but two days later the patient condition get deteriorated as he developed high grade fever, abdominal distention with rigidity and diffuse tenderness. So decision was taken for urgent diagnostic laparoscopy, after the initial laparoscopic port was placed, it was decided that completion of the laparoscopic procedure was not feasible due to the patient's distended bowel loops, and the procedure was converted to an open laparotomy in which the findings were gangrenous small bowel loop about 75 cm from the DJ junction, 60 cm of small bowel was resected. The patient eventually recovered from his illness and was discharged in a stable condition on oral anticoagulant.

Discussion

Portal vein thrombosis is a well-described, uncommon complication of operations that involve the portal or mesenteric veins. Although it is a rare complication of laparoscopic general surgery still it may be potentially catastrophic clinical complication due to mesenteric ischemia or infarction.(16) The etiology of PMVT complication after laparoscopic surgery is likely multifactorial, Some of the factors that may contribute to the pathogenesis of this condition include local injury near the portal flow, surgical damage (including direct trauma leading to diminished blood flow), prolonged time in the reverse Trendelenburg position, increased intra-abdominal pressure due to pneumoperitoneum, [17-21] and also

pneumoperitoneum with carbon dioxide causes sympathetic vasoconstriction through the release of vasopressors, which eventually reduces venous blood flow and increases the risk of thrombosis.[22,23] Possible etiologies other than surgery are: systemic (such as inherited hypercoagulable or acquired prothrombotic states) or local (such as intraabdominal inflammatory or neoplastic disease, diminished flow in cirrhosis, or portal hypertension). (17-21) finally bariatric patients themselves are at increased risk of post-surgical PMVT due to the presence of metabolic syndrome and the thromboembolic risk of obesity itself.

Several case reports and series (8,16-20,22,24,26,29-30) of PVT in the bariatric population have emerged as the prevalence of laparoscopic bariatric surgery has increased over the past decade. However, this is the first case series from Jordan to present PMVT, It is important to report such cases because this complication has subtle clinical presentation that may lead to delayed diagnosis and also to focus on the possible causes that was observed among our patients which could be modified in the upcoming patients.

PMVT seems to occur more frequently in patients undergoing LSG than in those undergoing other bariatric procedures. In our center although we had done 2342 LBS (1236 pts had Adjustable gastric band, 655 pts had LSG, and 451 pts had RNYGB) all the four cases of PMVT were post LSG.

The most significant contributing factors for PMVT during the LSG procedure are specifically:

- a. Thermal or mechanical effect on the short vessels or the left gastroepiploic arcade during the skeletonization of the greater curvature. Surgical manipulation intra-operatively can damage the splanchnic

endothelium and result in local thrombus formation which might then propagate throughout the portal venous system.

b. Ligation of the short gastric and tributary vessels which may affect the blood flow pattern and result in diminished flow.

c. Splenic vein or superior mesenteric vein (SMV) direct contact, which may occur during surgery and be the cause of thrombosis.

d. Splenic ischemia or infarction. The ligation of the short vessels during LSG may lead to insufficient perfusion of the upper pole of the spleen, perceptible as a demarcation during the operation. Such a condition, while asymptomatic in most cases, may occasionally lead to the symptomatic development of a splenic infarct and even subsequent abscess, reflecting the release of inflammatory mediators.

e. Dehydration. Commonly after bariatric surgery if patients had uneventful postoperative course, they are usually discharged from the hospital few days after the procedure. Some patients may have difficulty in reaching the targeted 2-L/d fluid intake and develop various degrees of dehydration, which predisposes them to VTE (including PMVT).(24) Also the liquid intake is limited after bariatric surgery due to the restrictive component of these surgeries, and some patients may be in a negative fluid balance after discharge. In our series, the median length of stay was 2 days, and in the four cases there was a history of decreased oral intake since the four patients presented with various degree of dehydration.

Our patients began experiencing new-onset epigastric pain, usually after being discharged from the hospital. This leads us to speculate that perhaps the relative

difficulty these patients have with fluid intake (a propensity for mild dehydration, together with the aforementioned risk factors for thrombosis) puts them at a greater risk for this rare complication.

The morbidity and mortality associated with PMVT is high due to the vague nature of the presenting symptoms, therefore leading to delay in diagnosis. [25] Clinical presentation may be subtle and requires a high index of suspicion, since these presentations may range from incidental findings, in an asymptomatic patient, to life-threatening bowel infarction. Pain out of proportion to physical findings specifically if it was associated with one or more risk factors should raise clinical suspicion and the necessary diagnostic workup should be performed without delay. (17) Most commonly, patients present postoperatively with non-specific abdominal pain, nausea, vomiting, and low-grade fever. Thus, physical examination findings can be normal, however, if associated with bowel ischemia, patients could present with septic shock and peritonitis. (16)

Laboratory values are most of the time within normal limits; so that normal blood tests do not exclude the diagnosis, however leukocytosis and mild elevation of liver function tests are also observed. The definitive diagnosis of PVT is made with noninvasive imaging. Actually diagnosis can be established with (oral and intravenous) contrast- enhanced CT which has been reported in published studies to diagnose and monitor the patient's course with a sensitivity of 90 %. [17, 26] PMVT was readily diagnosed using this modality for all the patients in our case series. Color Doppler ultrasonography may also be used. CT scans findings may include: small bowel wall thickening, mesenteric thickening, ascites, or contrast delay when entering the

portal venous system. [27] Diagnosis may also be made in the operating room, as in the fourth case in our series, since the bowel may look compromised and dusky, along with ascites. Keeping in mind that surgical exploration, preferably laparoscopic, may provide the definitive diagnosis when other modalities, including CT, yield negative or equivocal findings. (17)

Since the mortality rate of acute mesenteric thrombosis is 20% to 50%, (28) and recurrence is common within the first 30 days, once the diagnosis of PMVT is confirmed treatment should be promptly started. In patients presenting with peritonitis or shock, prompt exploration is needed with possible resection of necrotic bowel. Full therapeutic anticoagulation with either subcutaneous LMWH or intravenous unfractionated heparin is recommended in noncirrhotic, stable patients with acute PMVT who do not develop bowel ischemia or necrosis. (16,24) Therefore it has been recommended that patients with acute PMVT should be treated with anticoagulation therapy as early as possible, since it reduces the risk of further thrombotic events by enhancing the recanalization of the portal venous system (29) This treatment is continued and replaced by oral anticoagulants (target international normalized ratio, 2.5-3) for several months (the length of which will depend on a formal hematological consultation and the coagulation profile of the patient). (24) Aggressive intravenous hydration, total parenteral nutrition and bowel rest are important concomitant measures. A direct portomesenteric thrombectomy or thrombolysis is also possible in select cases. (19) No large studies exist to support the routine use of thrombolytics; however, this treatment has been shown to be effective in cases resistant to standard anticoagulation therapy. (16)

Although there is no consensus concerning PMVT prophylaxis, venous thrombotic event prophylaxis is routinely preoperatively administered as a standard prevention measure for DVT in most bariatric centers, however several studies suggest that the risk of thromboembolism post bariatric surgery continues long after discharge from the hospital, therefore prophylaxis should be continued for several weeks along the postoperative period. (16)

The four PMVT cases reported here are based on a single-center experience of over 2342 bariatric surgeries of which the majority was performed with the same surgical team. All of the four cases were post LSG. A history of decrease oral intake along with the presence of mild to moderate dehydration was the predominant risk factor for PMVT in our series, and abdominal pain was the main symptom. All patients were discharged home post their uneventful LSG and were doing well at their initial follow-up visit within the first 7 days of their operations. The symptoms of acute PMVT began on days 14, 18, 21 and 32 post operative for each of the 4 patients. Three of the patients presented with non-specific symptoms and the diagnosis was made by contrast-enhanced CT-scan, so that they were initiated on anticoagulation promptly, while the 4th case developed acute abdomen that needed surgical intervention with bowel resection. They all survived this complication.

Conclusion

Porto-mesenteric vein thrombosis is a rare but severe complication after laparoscopic bariatric surgery. Familiarity with this high-risk entity is critical. Early diagnosis and management, initiated by a high index of suspicion, is crucial. The state of dehydration post bariatric surgeries puts patients at a greater risk for this rare

complication. Contrast-enhanced abdominal and pelvic CT scan is the proven method of choice for PMVT diagnosis, however, if CT findings are equivocal or if the patient shows signs of deterioration, laparoscopic exploration is highly indicated. Early anticoagulation is the optimal treatment to avoid thrombosis progression and to achieve partial or complete recanalization. However surgical intervention is the choice when bowel necrosis develops.

References

- 1- Ögren M, Bergqvist D, Björck M, et al. Portal vein thrombosis: prevalence, patient characteristics and lifetime risk: a population study based on 23,796 consecutive autopsies. *World J Gastroenterology*. 2006; 12(13):2115–9.
- 2-Valla D, Condat B. Portal vein thrombosis in adults: pathophysiology, Pathogenesis and management. *J Hepatol*. 2000; 32(5):865–71.
- 3- Parikh S, Shah R, Kapoor P. Portal vein thrombosis. *Am J Med*. 2010; 123:111–119.
- 4- Fichera A, Cicchiello LA, Mendelson DS, Greenstein AJ, Heimann TM. Superior mesenteric vein thrombosis after colectomy for inflammatory bowel disease: a not uncommon cause of postoperative acute abdominal pain. *Dis Colon Rectum*. 2003; 46(5):643-648.
5. Rattner DW, Ellman L, Warshaw AL. Portal vein thrombosis after elective splenectomy: an underappreciated, potentially lethal syndrome. *Arch Surg*. 1993; 128(5):565-569; discussion 569-570.
6. Sanabria JR, Hiruki T, Szalay DA, Tandan V, Gallinger S. Superior mesenteric vein thrombosis after the Whipple procedure: an aggressive, combined treatment approach. *Can J Surg*. 1997; 40(6):467-470.
7. Stieber AC, Zetti G, Todo S, et al. The spectrum of portal vein thrombosis in liver transplantation. *Ann Surg*. 1991; 213(3):199-206.
- 8-James AW, Rabl C, Westphalen AC, Fogarty PF, Posselt AM, Campos GM. Portomesenteric venous thrombosis after laparoscopic surgery: a systematic literature review. *Arch Surg*. 2009; 144(6):520-526.
9. Jakimowicz J, Stultiens G, Smulders F. Laparoscopic insufflations of the abdomen reduces portal venous flow. *Surg Endosc*. 1998; 12:129 –132.
10. Takagi S. Hepatic and portal vein blood flow during carbon dioxide pneumoperitoneum for laparoscopic hepatectomy. *Surg Endosc*. 1998; 12:427–431.
- 11- Samama MM. An epidemiologic study of risk factors for deep vein thrombosis in medical outpatients: the Sirius study. *Arch Intern Med*. 2000;160 (22):3415–20.
- 12- Hansson PO, Eriksson H, Welin L, et al. Smoking and abdominal obesity: risk factors for venous thromboembolism among middle aged men: “the study of men born in 1913”. *Arch Intern Med*. 1999; 159(16):1886–90.
- 13- Gumbs AA, Gagner M, Dakin G, Pomp A. Sleeve gastrectomy for morbid obesity. *Obes Surg*. 2007; 17:962–969.
- 14- Rubin M, Yehoshua RT, Stein M, et al. Laparoscopic sleeve gastrectomy with minimal morbidity. Early results in 120 morbidly obese patients. *Obes Surg*. 2008; 18:1567–1570.
- 15- Bohdjalian A, Langer FB, Shakeri-Leidenmuhler S, et al. Sleeve gastrectomy as sole and definitive bariatric procedure: 5-

year results for weight loss and ghrelin. *Obes Surg.* 2010; 20: 535–40.

16- Rosenberg JM, Tedesco M, Yao D, et al. Portal Vein Thrombosis Following Laparoscopic Sleeve Gastrectomy for Morbid Obesity. *JLS* (2012)16:639–643

17- Swartz DE, Felix EL. Acute mesenteric venous thrombosis following laparoscopic roux-en-Y gastric bypass. *JLS*.2004; 8(2):165–9).

18- Bellanger DE, Hargroder AG, Greenway FL. Mesenteric venous thrombosis after laparoscopic sleeve gastrectomy. *Surg Obes Relat Dis.* 2010; 6(1):109–11.

19- Goitein D, Matter I, Raziell A, et al. Portomesenteric thrombosis following laparoscopic bariatric surgery: incidence, patterns of clinical presentation, and etiology in a bariatric patient population. *JAMA Surg.* 2013; 148(4):340–6.

20- Rottenstreich A, Khalailah A, Elazary R. Sleeve gastrectomy and mesenteric venous thrombosis: report of 3 patients and review of the literature. *Surg Obes Relat Dis.* 2014; 10(6):e57–61.

21- Takagi S. Hepatic and portal vein blood flow during carbon dioxide pneumoperitoneum for laparoscopic hepatectomy. *Surg Endosc.* 1998; 12(5):427–31.

22- Denne J, Kowalski C. Portal vein thrombosis after Laparoscopic gastric by-pass. *Obes Surg,* 2005; 15: 886–89

23-Poultides GA, Lewis WC, Feld R et al. Portal vein thrombosis after laparoscopic colectomy: thrombolytic therapy via the

superior mesenteric vein. *Am Surg,* 2005; 71: 856–60

24- Villagrán R, Smith G, Rodriguez W et al. Portomesenteric Vein Thrombosis After Laparoscopic Sleeve Gastrectomy: Incidence, Analysis and Follow-Up in 1236 Consecutive Cases. *Obes Surg Nov* 2016; 26, (11): 2555–2561

25- Divino C, Park I, Angel L et al. A retrospective study of diagnosis and management of mesenteric vein thrombosis. *Am J Surg* 2001;181: 20-3.

26- Johnson CM, de la Torre RA, Scott JS et al. Mesenteric venous thrombosis after laparoscopic roux-en-Y gastric bypass. *Surg Obes Relat Dis.* 2005; 1(6):580-583.

27- Harris J, Blackwood B, Pillai S et al. Mesenteric vein thrombosis following laparoscopic appendectomy. *J Ped Surg Case Reports* 2014; (2): 495-497

28- Morasch MD, Ebaugh JL, Chiou AC et al. Mesenteric venous thrombosis: A changing clinical entity. *J Vasc Surg.* 2001; 34: 680-684.

29- Muneer M, Abdelrahman H, El-Menyar A et al. Portomesenteric Vein Thrombosis After Laparoscopic Sleeve Gastrectomy: 3 Case Reports and a Literature Review. *Am J Case Rep,* 2016; 17: 241-247

30- Belnap L, Rodgers G, Cottam D et al. Portal vein thrombosis after laparoscopic sleeve gastrectomy: presentation and management. *Surg Obes Relat Dis.* Dec 2016; 12 (10):1787-1794.

Figure 1

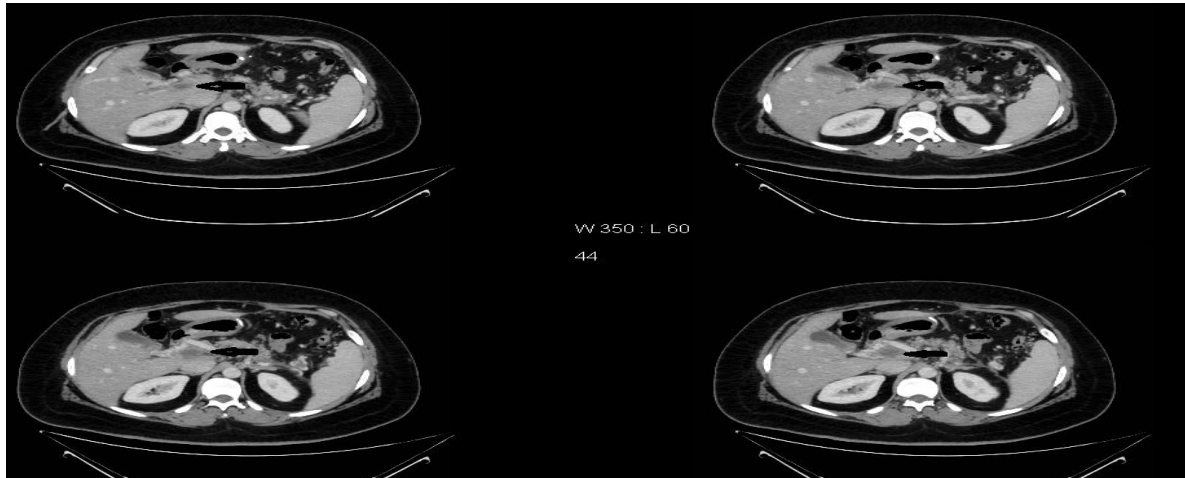


Figure 2

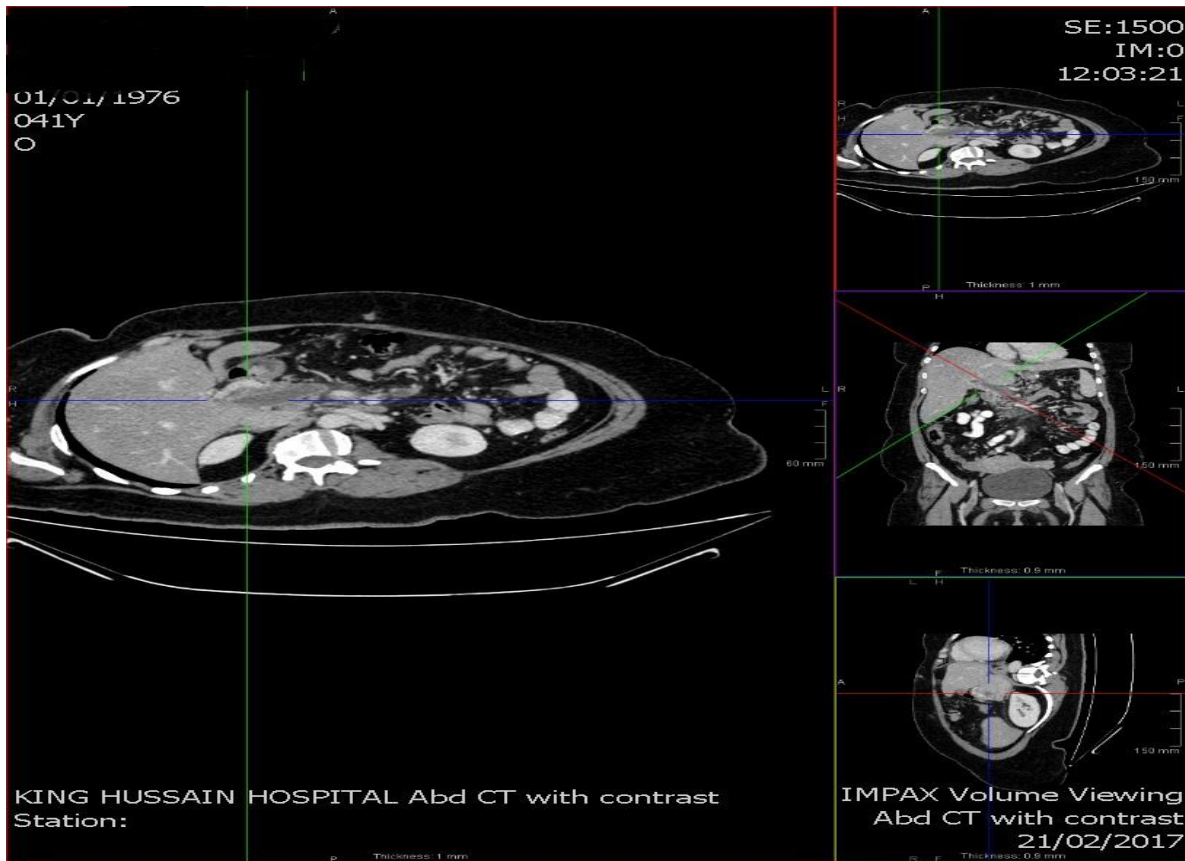


Figure 3, 4, 5, 6

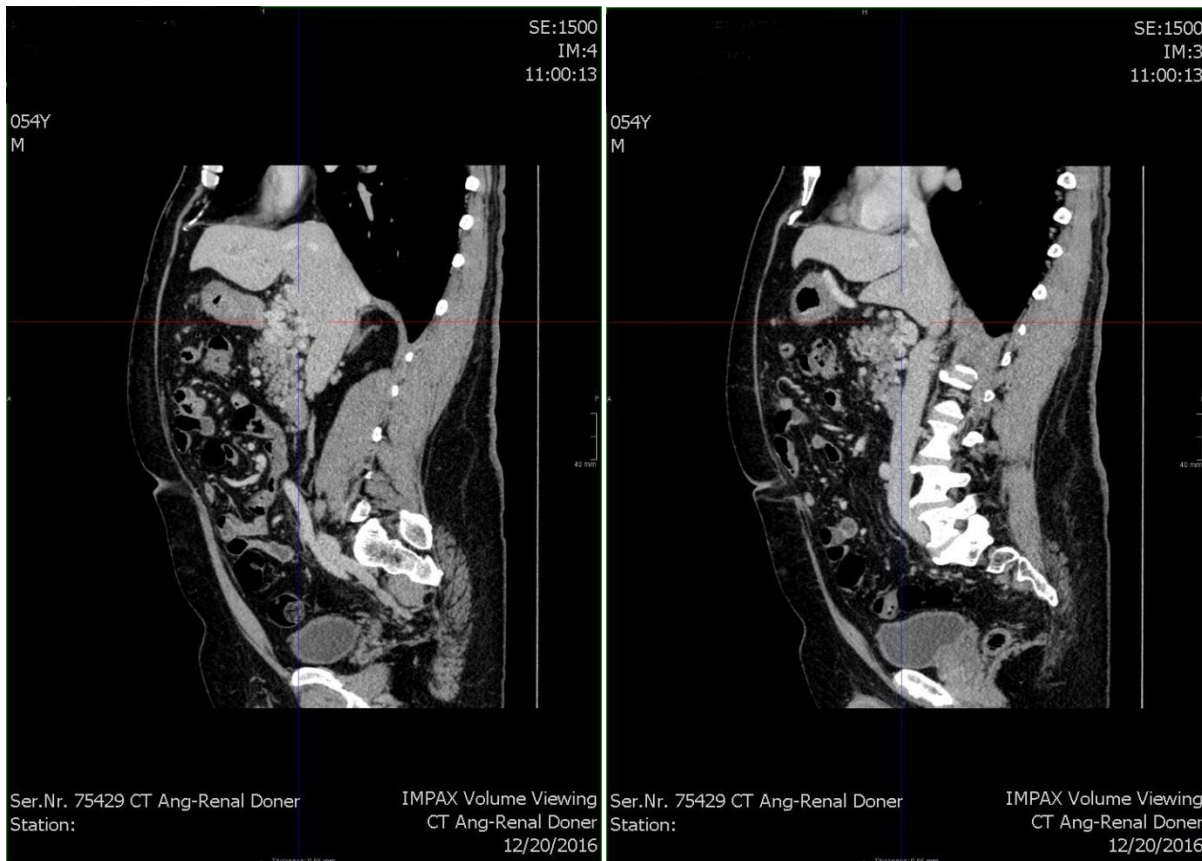
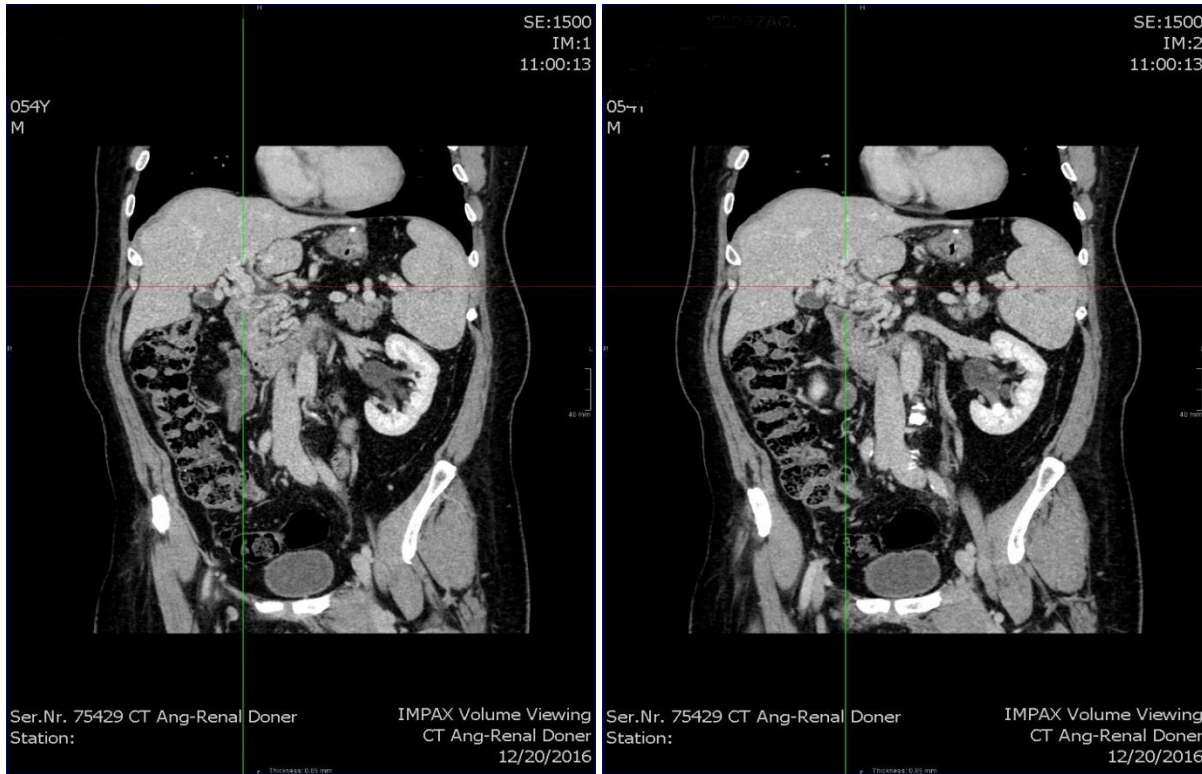


Figure 7, 8

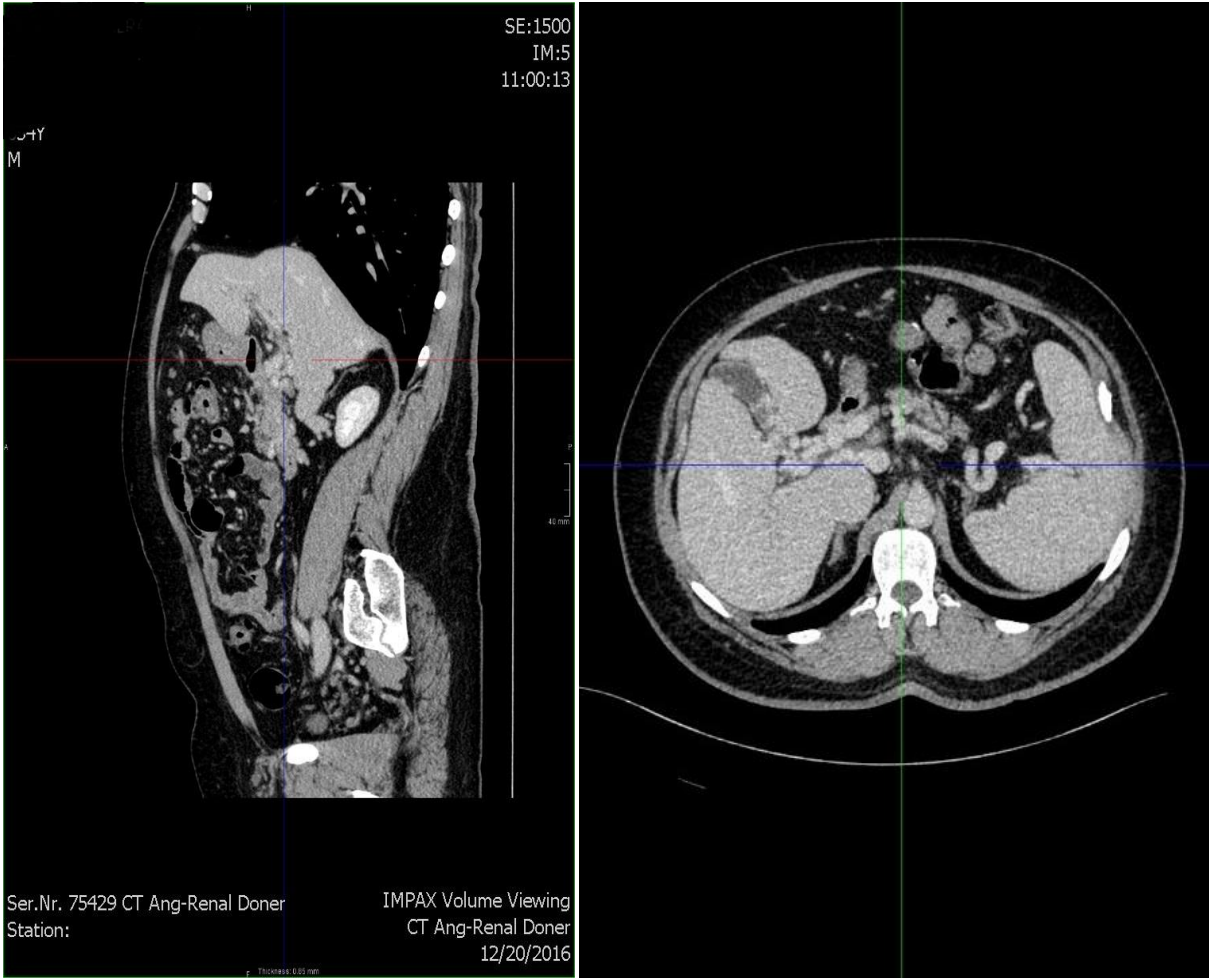


Figure 9, 10, 11, 12

