

Case report

Kerion caused by Trichophyton Mentagrophytes most probably acquired from one gymnasium in 2 athletic boys

Shahriar Alian¹, Iman Sadeghian², Fatemeh Ahangarkani², Arghavan Amouzgar²

1- Antimicrobial resistance research center, mazandaran university of medical sciences, sari, Iran

2- Student research committee, antimicrobial resistance research center, mazandaran university of medical science, Sari, Iran

Corresponding author: Arghavan Amouzgar.

Email: persian.doctor.arghavan@gmail.com

Abstract

Two 8 and 10 year- old athletic boys lived in Qaemshahr urban area (in north of Iran) presented by erythematous plaques with follicular postules on head area extending from right occipital to right temporal regions with itching and hair loss about 2 weeks prior their initial visit when the itching and postules and hair loss increased. The diagnosis was Kerion. Endothrix hyphea was seen within hair shaft and Trichophyton Mentagrophytes was isolated from scales and tissue taken from lesions on the head. Postules disappeared 3-4 weeks after oral treatment with terbinafine 125 mg daily. No recurrence has been observed to date.

Keywords: Kerion, tineacapitis, Trichophyton Mentagrophytes

Introduction

Dermatophytosis represents one of the most common infectious diseases worldwide and causes serious chronic morbidity(1). The condition is caused by dermatophytes, which are fungi that require keratin for growth. An increase in the incidence of such infections has been noted worldwide, especially in developing countries(2, 3). In particular, *tineacapitis* represents a major public health issue among children in developing countries. Many factors including gender, age, urban/rural environment, socio-economic level and cultural habits have been shown to significantly impact the development of dermatophytosis worldwide, especially throughout the African continent (4-8). Tinea capitis or scalp ringworm is a disease of childhood that boys less than 15 years old are more susceptible for this disease, the disease is widespread in some urban areas in Asia, Africa, Mexico (6, 7). Although recently in modern world, kerions infrequently seen. In most kerions, the pustule is not a sign of secondary bacterial infection. The main clinical feature in this type of dermatophyte scalp infection is appearance of scaling the scalp skin that associated with variable degree of inflammation, erythema and alopecia. The infection is often with itching(6, 7). Although Griseofulvin is drug of choice, but Terbinafine because of shorter course of treatment

and lesser side effects than Griseofulvin is better recommended (4, 8-10). Treatment duration should be individualized according to severity and clinical response(8). Adjunctive treatment is controversial but data does not support antibiotics nor surgery for routine use(11).

Case report 1

A 8 year old athletic boy in Qaemshahr urban area north of Iran who presented by erythematous pruritic plaques with follicular postules and painful nodules on his scalp from right occipital to right temporal area with hair loss since 2 weeks prior initial visit when the pruritus and hair loss increased.[Figure 1] He was athletic and quite healthy without any underlying disease and immunity disorders. He had no contact with soil and pet animals. In home and his school and gymnasium no body was affected with like the lesions. In physical examination fever was not detected but cervical lymphadenopathy was noted. In direct smear with KOH and endothrixhyphea within hair shaft was seen, Trichophyton Mentagrophytes was isolated from lesions on head. Oral treatment began with terbinafine (because of shorter course of treatment and lesser side effects) 125 mg daily for 4-6 weeks and pustules disappeared 3-4 weeks after starting oral treatment

with areas of alopecia [Figure 2] and he is required to wear a wig. No recurrence has been observed to date.

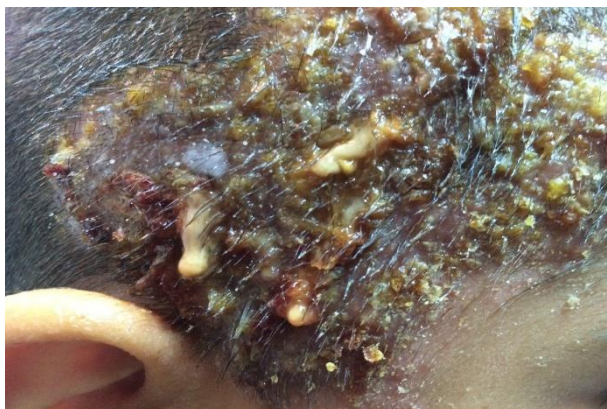


Figure 1: Case number 1 before treatment

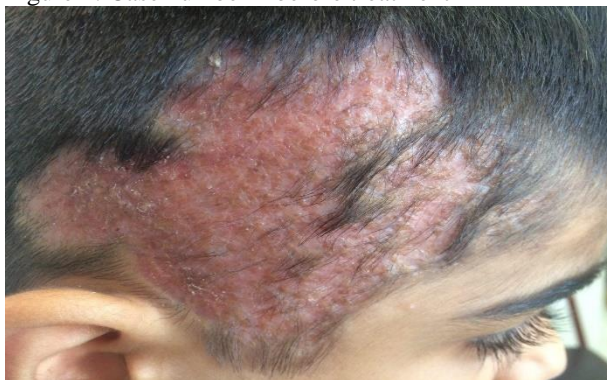

Figure 2: Case number 2 after treatment

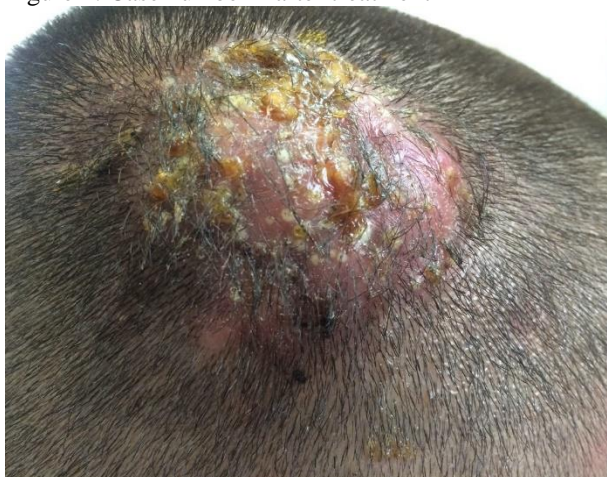

Figure 3: Case number 2 before treatment

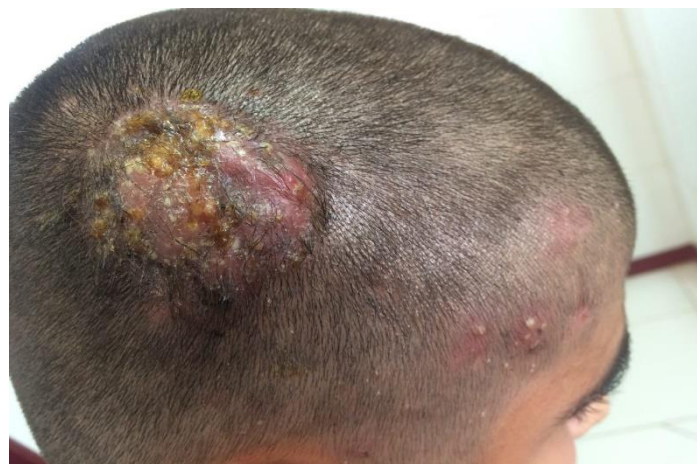

Figure 4: Case number 2 after treatment

Case 2 :

A 10 years athletic boy played in the same gymnasium came 2 months after the case 1 with folliculopostular lesions on right temporal part of his head with secondary bacterial super infection. [Fig 3] . He was quite healthy and without any underlying disease or immunity disorder. The patient admitted for evaluation and treatment. Trychophyton Mentagrophytes isolated from head scalp lesions and oral treatment with terbinafin and anti-bacterial drugs began for bacterial superinfections. Bacterial superinfection removed after 5 days. Antifungal treatment continued 2 months and the scars was less than our expectation. [Fig 4]. No recurrence has been observed to date.

Discussion

Tinea capitis is predominantly seen in prepubertal and pre school children but in recent years due to improvements in health status the incidence of some disease is reduced and medical students rarely meet such cases. Therefore the patients may be misdiagnosed and almost wrong or late management may cause sequels. Although tinea is prepubertal children disease but Sombatmaithai et al reported scalp tinea with unusual clinical manifestations due to *T. tonsurans* in one 38 years old woman that she was teacher of children primary school and had contact with children. The patient had asymptomatic, dry and scaly patches alopecia. and definitive diagnosis was confirmed by biopsy and histopathology . Treatment done with anti fungal shampoo for sevsral years {Ameen, 2010 #2}.

Most of studies about scalp tinea have been conducted in rural areas. There are few studies or

none among school going children from urban crowded areas. In studies by Moto et al from Ethiopian and Tanzania and Kenya evaluated dermatological infection among school going children from informal settlement. This study reported an overall prevalence of 81.2% (122/150). This rate was found to be higher than those obtained in Ethiopian (59%), Tanzania (4%), and those previous conducted in Kenya (33.3%). *Trichophyton* species had the highest prevalence of 61.3%, with *T. tonsurans* (33.3%). These findings were similar to other studies from Kenya and Nigeria. For *Trichophyton mentagrophytes* (6.7%), the findings were similar to other sub-Saharan countries of 7.3–15.7 % { Moto, 2015 #20}.

Brissos et al reported a healthy 3-year-old boy presented with a 2-week history of inflammatory scalp diffuse erythematous lesions, with focal areas of alopecia and several pustular patches with extensive suppurative discharge .Cervical lymphadenopathy and fever were noted .Diagnosis performed from scalp lesions by surgical drainage .*Trichophyton mentagrophytes* was isolated from scalp. Treatment done with 5-month course of fluconazol{Brissos, 2013 #12}

In our 2 cases *Trichophyton* species was *Mentagrophytes* and they treated with oral terbinafine for two months. No one of 2 athletic boys had not contact with animals and they lived in urban areas. Their parents reported same fungal infections (skin lesions on leg).

Conclusion

Tinea capitis is a superficial fungal infection of scalp and one of the most common dermatophytosis of childhood. The most inflammatory presentation is kerion, which is considered to be an exaggerated cell-mediated response to the fungus, and often confused with a bacterial infection.

There is a need to improve hygienic standards in public places like gymnasiums. A need to check on antiseptic procedures used by barbers and advise them on correct procedures to be implemented. There is a need to have a regular epidemiological surveillance of causative fungal organisms in an essential component in the management of this condition. Tineacapitis should be considered any type of scalp lesions . This problem needs to careful consideration , good follow up , and epidemiologic studies. In this case the most probably source of the infection was poor hygienic gymnasium.The gymnasium was in ground floor and was light but because of poor hygiene the 2 boy and another athletics was affected with tinea capitis.

References

- .1 Moriarty B, Hay R, Morris-Jones R. The diagnosis and management of tinea. BMJ. 2012;345(7865):37-42.
- .2 Ameen M. Epidemiology of superficial fungal infections. Clinics in dermatology. 2010;28(2):197-201.
- .3 Singh S, Beena P. Comparative study of different microscopic techniques and culture media for the isolation of dermatophytes. Indian journal of medical microbiology. 2003;21(1):21.
- .4 Blank H, Taplin D, Zaias N. Cutaneous *Trichophyton mentagrophytes* infections in Vietnam. Archives of dermatology. 1944-135;(2)99;69
- .5 Hogewoning A, Amoah A, Bavinck JNB, Boakye D, Yazdanbakhsh M, Adegnik A, et al. Skin diseases among schoolchildren in Ghana, Gabon, and Rwanda. International journal of dermatology. 2013;52(5):589-600.
- .6 Vena GA, Chieco P, Posa F, Garofalo A, Bosco A, Cassano N. Epidemiology of dermatophytoses: retrospective analysis from 2005 to 2010 and comparison with previous data from 1975. Microbiologica-Quarterly Journal of Microbiological Sciences. 2012;35(2):207.
- .7 Yazdanfar A. Tinea capitis in primary school children in Hamedan (West of Iran). International Journal of Medicine and Medical Sciences. 2010;2(2):029-33.
- .8 Kakourou T, Uksal U. Guidelines for the management of tinea capitis in children. Pediatric dermatology. 2010;27(3):226-8.
- .9 Grover C, Arora P, Manchanda V. Comparative evaluation of griseofulvin, terbinafine and fluconazole in the treatment of tinea capitis. International journal of dermatology. 2012;51(4):455-8.
- .10 Higgins E, Fuller L, Smith C. Guidelines for the management of tinea capitis. British Journal of Dermatology. 2000;143(1):53-8.
- .11 von Laer Tschudin L, Laffitte E, Baudraz-Rosselet F, Dushi G, Hohlfeld J, de Buys Roessingh AS. Tinea capitis: no incision nor excision. Journal of pediatric surgery. 2007;42(8):e3-3e6.