

Original Article**Are Topical Nonsteroidal Anti-inflammatory Drugs Effective on Cataract Surgery Outcome in Pseudoexfoliation Syndrom?**Mitra Akbari^{*1}, Reza Soltani Moghadam², Anvar Mohamadpour³

1- M.D. Associate Professor of Ophthalmology, Cornea and Anterior Segment Fellowship, Eye Research Center, Department of Eye, Amiralmomenin Hospital, School of Medicine, Guilan University of Medical Science, Rasht, Iran.

2- M.D. Associate Professor of Ophthalmology, Cornea and Anterior Segment Fellowship, Eye Research Center, Department of Eye, Amiralmomenin Hospital, School of Medicine, Guilan University of Medical Science, Rasht, Iran.

3- M.D. Ophthalmologist, Eye Research Center, Department of Eye, Amiralmomenin Hospital, School of Medicine, Guilan University of Medical Science, Rasht, Iran.

***Corresponding author:** Mitra Akbari, Eye Research Center, Department of Eye, Amiralmomenin Hospital, School of Medicine, Guilan University of Medical Science, Rasht, Iran. E-mail: mitra.akbari20@gmail.com, <https://orcid.org/0000-0003-2469-2681>

Abstract:

Background: Patients with pseudo-exfoliation syndrome (PEX) have a higher risk of inflammation after phacoemulsification surgery that can result in several complications in anterior and posterior segments. The present study aimed to evaluate the effect of adding topical ketorolac to steroids on anterior segment inflammation and complications.

Methods: In this randomized clinical trial, 88 patients with cataract and PEX, candidate of phacoemulsification surgery, were randomized to receive either 5% chloramphenicol + 0.1% betamethasone with or without 0.5% ketorolac tromethamine eye drops for two weeks. Anterior chamber inflammation (ACI), intraocular pressure (IOP), and best corrected visual acuity (BCVA) were recorded 1, 3, 7, and 30 days after surgery and the degree of opacity of the anterior capsule (ACO) and opacity of the posterior capsule (PCO) six months after surgery were compared between the two groups using SPSS v.21.

Results: Forty-six patients were evaluated in ketorolac group and 42 in the control (without ketorolac). IOP and BCVA were not different between two groups on days 1, 3, 7, and 30 after surgery ($P > 0.05$). However, the group using ketorolac had less ACI on days 3, 7, and 30 after surgery ($P < 0.05$) and lower degrees of ACO and PCO six months after surgery ($P < 0.05$).

Conclusion: Addition of ketorolac eye drop to steroid eye drop after cataract surgery had additional effect on reducing ACI after cataract surgery in patients with cataract and PEX with additional effect on reducing ACO, and PCO.

Keywords: Cataract; Ketorolac; Exfoliation Syndrome

Submitted: 17 November 2021, Revised: 15 November 2021, Accepted: 18 December 2021

Introduction

Cataract is the main cause of blindness, responsible for one in three blind cases worldwide (1), and the top cause of blindness in the elderly (2). Replacement of the opacified intra ocular lens (IOL) with a crystalline artificial lens through surgery is the main treatment of cataract (3), performed by several techniques; phacoemulsification is one of the most commonly performed procedures (4). Generally speaking, cataract surgery is a safe procedure with low risk of serious complications, including capsule rupture, infected endophthalmitis, choroidal or suprachoroidal hemorrhage, and retinal detachment; but there are other complications that do still occur and can impair the patients' visual acuity or cause other problems for the patients (5, 6).

Concomitant ocular diseases, like pseudoexfoliation syndrome (PEX), which weaken the capsule and zonular apparatus, can predispose the patients to intra and postoperative complications (7). In this systemic disease, distinctive fibrillar material is deposited in the anterior segment of the eye (as well as other parts of the body), which can increase the risk of postoperative anterior chamber inflammation (ACI), lens dislocation and vitreous loss, postoperative IOP spikes, capsular phimosis, and postoperative corneal decompensation (8). Therefore, studies have suggested additional measures to be taken for this group of patients for reducing the risk of intra- and post-operative complications after phacoemulsification surgery (9, 10), although some suggest that the performance of phacoemulsification surgery by experienced hands can also omit the risk of increased complications in cataractous eyes with PEX (11).

Inflammation is one of the important postoperative complications of cataract surgery

and eye drops are prescribed routinely after surgery for prevention of inflammation; the most commonly drugs used for this purpose include steroids and non-steroid anti-inflammatory drugs (NSAIDs) (12). However, studies have investigated the efficacy of either of these two on postoperative complications and compared them with each other (12) and as far as we are concerned, the additional effect of NSAIDs to steroids have been scarcely evaluated in patients with PEX after phacoemulsification surgery for cataract; some have suggested significant priority for addition of NSAIDs to steroids (13), while others have shown no significant difference (14). As the duration of follow-up, type of the prescribed NSAIDs/steroids, and the studied outcomes were dissimilar and definite conclusion cannot be derived from these studies, the present study aimed to evaluate the effect of adding ketorolac eye drop to topical steroids on the patients' postoperative inflammation and anterior segment complications.

Methods

In the present randomized clinical trial (RCT), patients, who referred to Amir-al-Momenin Hospital, Rasht, Iran, from October 2016 until May 2019, diagnosed with cataract >grade III with PEX and indicated for phacoemulsification surgery were considered as the study population. The protocol of the study was approved by the Ethics Committee of Guilan University of Medical Sciences and registered in the Iranian registry of clinical trials by the code IRCT20160919029871N3.

An ophthalmic surgeon examined all patients and the cataract grade was diagnosed using the Oxford clinical cataract classification and grading system, and PEX was diagnosed during slit lamp examination. Patients with hypersensitivity to any component of NSAIDs, chronic uncontrolled ocular or systemic disease, ocular inflammation or trauma,

patients who underwent other types of cataract surgery (like extracapsular and intracapsular methods), and patients who used NSAIDs up to one week before surgery or steroids up to two weeks before surgery in any forms (oral, inhaled, or local) were not included in the study.

The design and objectives of the study were explained to the eligible patients and they were asked to read and sign the written informed consent for their participation in the study. The sample size of the study was calculated at 92 participants based on the study by Coassin and colleagues (14); considering the confidence interval of 99% and study power of 90%. All participants underwent standard phacoemulsification surgery by a single surgeon using 2.8-mm temporal incision and placement of *enVista*® acrylic hydrophobic IOL in lens capsule with capsulorrhexis diameter of 5-6mm. The day after surgery, all patients received 5% chloramphenicol (Chlobiotic; Sina Company, Iran) and 0.1% betamethasone (the same company) two drops in each eye every four hours until two weeks after surgery and then every eight hours until two other weeks (total of one month). The participants were divided into two groups using simple randomization method, block size of 4, with a 1:1 ratio. In one group, in addition to these two, 0.5% ketorolac tromethamine (Sinarolac, the same company) was also administered every six hours for 15 days, named as ketorolac group. The patients were not aware of the group they were allocated to (were blind) and the study was single-blinded.

The participants' demographics, including age and sex, were recorded. Patients were visited on days 1, 3, 7, 30, and 6 months after surgery and the results of anterior and posterior segment examinations were recorded, which included ACI, IOP, and best corrected visual acuity (BCVA) and were considered as the primary outcome of the study. ACI was

measured on days 1, 3, 7, and 30 after surgery and reported based on cell count and flare classification on slit lamp examination; the percentage of subjects with this condition were reported based on protein content and rated according to Standardization of Uveitis Nomenclature working group grading (15) from zero to four; 0:none, 1⁺:faint, 2⁺:moderate (iris and lens details clear), 3⁺:marked (iris and lens details hazy), and 4⁺:intense (fibrin or plasmoid aqueous). IOP was measured using Goldman Applanation Tonometry and BCVA using Snellen chart and reported based on Log MAR.

Also, after six months, the degree of opacity of the anterior capsule (ACO) and opacity of the posterior capsule (PCO) were evaluated by slit lamp examination and scored from zero to four. PCO was graded as 0 (none) when there was no evidence of PCO; grade 1 (trace), when there was few discrete epithelial pearls; grade 2 (mild), when there was multiple discrete epithelial pearls; grade 3 (moderate), when there were multiple coalescent epithelial pearls; and grade 4 (severe), when there were thick sheets of epithelial pearls (16). ACO was graded as 0 (clear), when anterior capsule was transparent; grade I when opacification was localized at the edge of the capsulorrhexis; grade II when moderate and diffuse opacification, sometimes with areas of capsular folding were observed, grade III when intense opacification, with areas of capsular folding were observed and grade IV when constriction (phimosis) of the capsulorrhexis opening (capsulorrhexis diameter <3.5 mm) was seen. All the patients' examination and surgical procedures and post op follow-up examination performed by one anterior segment surgeon (M.A).

Patients who used prostaglandin analogues for treatment of glaucoma, their medication were substituted with another anti-glaucoma medication. Any patient who developed intra-

operative complications, such as posterior capsule rupture and vitreous loss,

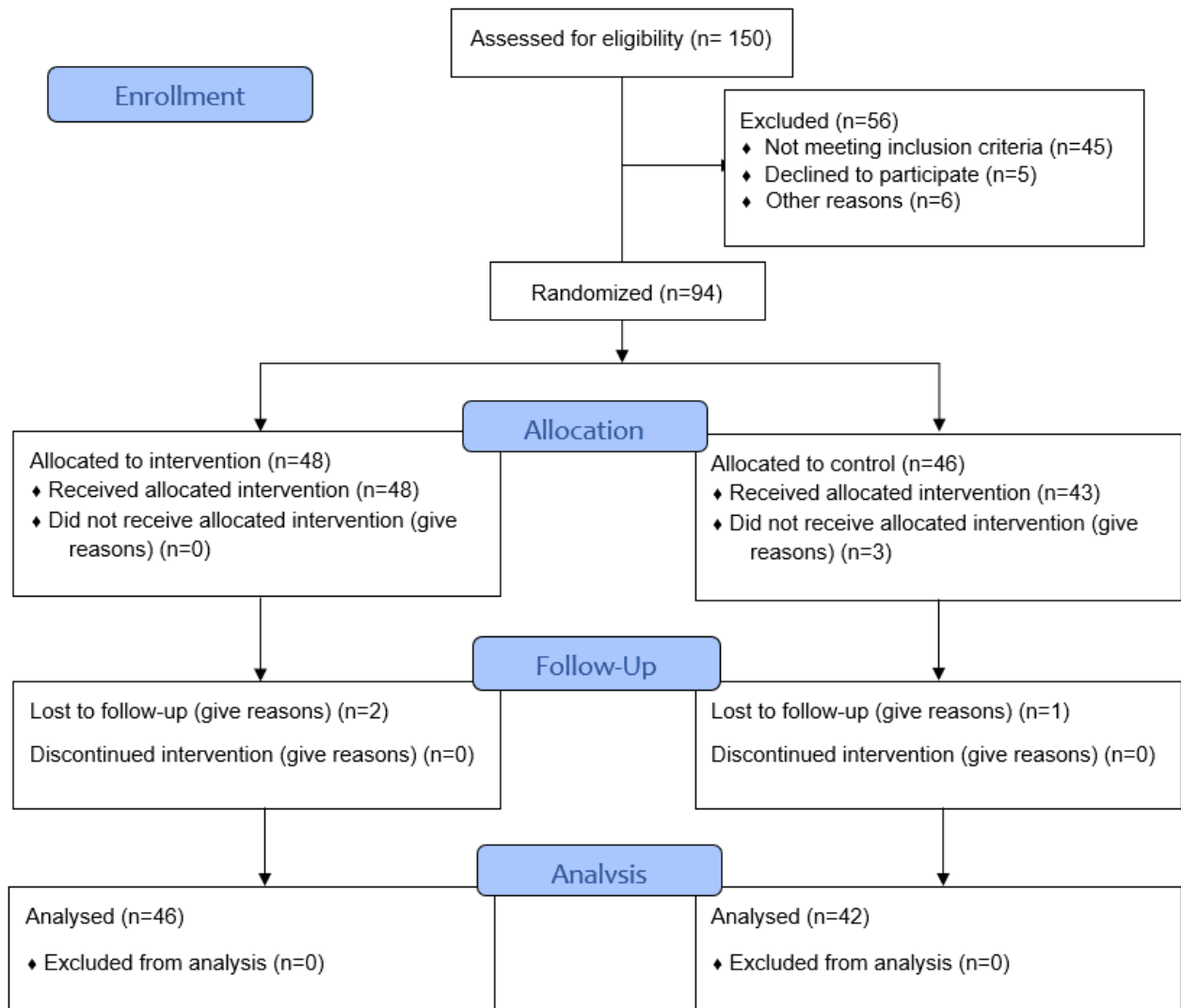


Figure 1. Flow diagram for participant screening and enrollment for this study

and those who required systemic NSAIDs or corticosteroids (due to severe postsurgical inflammation) were excluded from the study.

Statistical analysis

Descriptive results were presented by frequency (percentage) and mean \pm standard deviation (SD). The results of One-sample Kolmogorov–Smirnov test was used for determination of the normal distribution of data and accordingly, numeric variables were compared between the groups using *t* test or Mann-Whitney U test. Chi square and Fisher's exact tests were used for comparing the categorical variables between the two study

groups. The effect of time was evaluated using repeated measures ANOVA or its non-parametric test, Friedman test; significant differences were compared pairwise using Tukey's post hoc test. Data were analyzed using the statistical software IBM SPSS Statistics for Windows version 21.0 (IBM Corp. 2012. Armonk, NY: IBM Corp). P values <0.05 were considered statistically significant.

Results

Forty-six patients in ketorolac group and 42 in the control group completed the study (Figure 1). The demographic characteristics of the participants are shown in table 1.

Table 1. The demographic characteristics of the participants and their comparison between the two groups of the study

Variables	Categories	Total	Ketorolac group (N=46)	Control group (N=42)	p-value
Age categories (years), No.(%)	≤60	9(10.23)	3(6.52)	6(14.29)	0.486*
	61-70	27(30.68)	14(30.43)	13(30.95)	
	>70	52(59.09)	29(63.04)	23(54.76)	
Age (years), mean ± SD		71.58±7.82	71.96±7.06	71.17±8.65	0.639†
Sex, No (%)	Male	41(46.59)	21(45.65)	20(47.62)	0.853‡
	Female	47(53.41)	25(54.35)	22(52.38)	

*The results of Fisher's exact test; †The results of independent samples *t* test; ‡The results of Chi square test

Table 2. Comparing the best corrected visual acuity of the participants in the measured intervals based on Log-MAR between the two study groups

Variables		Total	Ketorolac group (N=46)	Control group (N=42)	p-value*
Before surgery	mean±SD	1.11±0.39	1.15±0.36	1.15±0.36	0.449
	Median	1.04	1.13	1.00	
One day after surgery	mean±SD	0.73±0.29	0.81±0.27	0.85±0.31	0.326
	Median	1.00	1.00	1.00	
Compared with presurgical status	mean±SD	-0.30±0.26	-0.35±0.19	-0.25±0.31	0.171
	Median	-0.30	-0.30	-0.30	
Three days after surgery	mean±SD	0.73±0.28	0.70±0.27	0.77±0.29	0.301
	Median	0.70	0.70	1.00	
Compared with presurgical status	mean±SD	-0.40±0.29	-0.46±0.25	-0.32±0.31	0.027
	Median	-0.39	-0.48	-0.30	
Seven days after surgery	mean±SD	0.61±0.28	0.57±0.25	0.66±0.30	0.141
	Median	0.70	0.52	0.70	
Compared with presurgical status	mean±SD	-0.51±0.26	-0.58±0.19	-0.43±0.30	0.027
	Median	-0.48	-0.48	-0.48	
One month after surgery	mean±SD	0.45±0.22	0.42±0.21	0.48±0.23	0.173
	Median	0.40	0.40	0.52	
Compared with presurgical status	mean±SD	-0.67±0.29	-0.74±0.26	-0.60±0.30	0.155
	Median	-0.70	-0.70	-0.66	
Six months after surgery	mean±SD	0.34±0.20	0.33±0.19	0.36±0.20	0.488
	Median	0.30	0.30	0.30	
Compared with presurgical status	mean±SD	-0.77±0.32	-0.83±0.29	-0.77±0.32	0.191
	Median	-0.78	-0.78	-0.74	

*The results of Mann-Whitney U test

As indicated, the two study groups were not different in terms of mean age, distribution of age categories, and sex ($P>0.05$). The results of BCVA examination showed that the groups were not different in this regard at any of the measured intervals ($P>0.05$; table 2), while the results of Friedman test showed that the effect of time was significant and both groups had a better BCVA after surgery (both $P<0.001$). Comparing the mean difference of the BCVA values with presurgical state showed significant improvement three and seven days after surgery (Both $P=0.022$), but not in one and six months after surgery ($P>0.05$; table 2).

The results of IOP examination showed that the groups were not different in this regard at any of the measured intervals ($P>0.05$; table 3), while the results of Friedman test showed that the effect of time was significant and both groups had a lower IOP after surgery (both $P<0.001$). Comparing the mean difference of the IOP values with presurgical state showed significantly different IOP in ketorolac group one month after surgery ($P=0.027$), while there was no difference between the groups in other intervals ($P>0.05$; table 2).

The distribution of ACI was significantly different between the study groups according to Flare and cell count classification on days 3, 7, and 30 after surgery, as shown in table 4; at all intervals, the frequency of higher grades of inflammation was higher in the control groups. The results of Friedman test showed that the effect of time was significant in both groups (both $P<0.001$) and there were significant differences between 7 days after surgery and one day after surgery in both groups (both $P<0.001$), one month after surgery vs. one day after surgery in both groups (both $P<0.001$), and one month after surgery vs. three days after surgery in both groups (both $P<0.001$).

As indicated in table 5, PCO and ACO were significantly different between the two groups

($P=0.002$ and 0.001 , respectively) and there were no case of PCO grade III and ACO grades III and IV in ketorolac group (table 5).

Discussion

The results of comparing two groups with similar demographics in the present single-blind RCT showed that the visual acuity of all participants improved (in both groups), which confirmed the efficacy of the performed surgical procedure with the prescribed drugs on improvement of patients' visual acuity, although patients with PEX are suggested to have a lower BCVA compared to non-PEX patients after phacoemulsification (17, 18). Sastry and Singal reported mean BCVA of 1.02 ± 0.64 on day one after cataract surgery in PEX patients. (17), which was higher than expected and higher than the mean BCVA of our patients at this time (0.73 ± 0.29). The results of comparing two groups in our study showed that Ketorolac group had a higher mean change in BCVA three and seven days after surgery, while mean BCVA were not different between the two study groups at the studied intervals. These results showed that the addition of ketorolac to steroids did not result in significant change in postoperative visual acuity of patients with PEX after phacoemulsification. In the study by Coassin and colleagues, patients with PEX undergoing cataract surgery were randomized to 0.1% dexamethasone and 0.3% tobramycin with or without 0.09% bromfenac and the results showed that the postoperative visual acuity of the two groups were not different (14), which is consistent with the results of the present study, although the type of NSAID and steroid prescribed differed. Steroids and NSAIDs are considered effective for prevention of inflammation after cataract surgery; but, mainly either of them is prescribed (19). In a review of 15 RCTs, the visual acuity of patients after cataract surgery showed no statistically

significant difference between patients who received NSAIDs or steroids (12).

Table 3. Comparing the intraocular pressure of the participants in the measured intervals between the groups

Variables		Total	Ketorolac group (N=46)	Control group (N=42)	p-value*
Before surgery	mean±SD	16.23±2.92	16.54±2.65	15.88±3.19	0.675
	Median	16.00	16.00	16.00	
One day after surgery	mean±SD	17.72±2.46	17.67±2.68	27.76±2.23	0.679
	Median	17.00	17.00	17.50	
Compared with presurgical status	mean±SD	1.49±2.43	1.13±1.15	1.88±3.28	0.641
	Median	1.00	1.00	1.00	
Three days after surgery	mean±SD	17.45±2.19	17.35±2.29	17.57±2.09	0.478
	Median	17.00	17.00	17.00	
Compared with presurgical status	mean±SD	1.23±2.42	0.80±1.20	1.69±3.22	0.302
	Median	1.00	1.00	1.00	
Seven days after surgery	mean±SD	17.06±1.84	16.87±1.96	17.26±1.70	0.235
	Median	17.00	17.00	17.00	
Compared with presurgical status	mean±SD	0.83±2.52	0.33±1.16	1.38±3.38	0.095
	Median	1.00	1.00	1.00	
One month after surgery	mean±SD	16.81±1.81	16.67±1.93	16.95±1.68	0.370
	Median	16.5	16.00	17.00	
Compared with presurgical status	mean±SD	0.58±2.25	0.13±1.20	1.07±2.95	0.022
	Median	0	0	1.00	
Six months after surgery	mean±SD	16.70±1.92	16.62±1.98	16.78±1.86	0.517
	Median	16.00	16.00	17.00	
Compared with presurgical status	mean±SD	0.49±2.24	1.19±0	2.95±1.00	0.055
	Median	1.00	1.00	1.00	

*The results of Mann-Whitney U test

Table 4. Comparing the inflammation grades of the participants in the measured intervals between the two study groups according to Flare classification and cell count

	Variables	Grade	Total	Ketorolac group (N=46)	Control group (N=42)	p-value
Flare classification	One day after surgery	0	20(22.73)	13(28.26)	7(16.67)	0.372*
		1	39(44.32)	17(39.96)	22(52.38)	
		2	24(27.27)	14(30.43)	10(23.81)	
		3	5(5.68)	2(4.35)	3(7.14)	
	Three days after surgery	0	18(20.45)	15(32.61)	3(7.14)	0.005*
		1	53(60.23)	26(56.52)	27(64.29)	
		2	17(19.32)	5(10.87)	12(28.57)	
	Seven days after surgery	0	39(45.88)	29(65.91)	10(24.39)	<0.001 [†]
		1	43(50.59)	15(43.09)	28(68.29)	
		2	3(4.53)	0	3(7.32)	
	One month after surgery	0	60(73.17)	39(95.12)	21(51.22)	<0.001*
		1	22(26.83)	2(4.88)	20(48.78)	
Cell count	One day after surgery	0	6(6.82)	3(6.52)	3(7.14)	0.824 [†]
		1	48(54.55)	24(52.17)	24(57.14)	
		2	31(35.23)	18(39.13)	13(30.95)	
		3	3(3.41)	1(2.17)	2(4.76)	
	Three days after surgery	0	6(7.06)	5(11.63)	1(2.38)	0.007 [†]
		1	60(70.59)	34(79.07)	26(61.90)	
		2	18(21.18)	4(9.30)	14(33.33)	
		3	1(1.18)	0	1(2.38)	
	Seven days after surgery	0	25(32.89)	22(53.66)	3(8.57)	<0.001 [†]
		1	46(60.53)	19(46.34)	27(77.14)	
		2	5(6.58)	0	5(14.29)	
	One month after surgery	0	54(73.97)	40(97.56)	14(43.75)	<0.001*
		1	19(26.03)	1(2.44)	18(56.25)	

*The results of Chi square test; [†]The results of Fisher's exact test; all values are reported as No.(%)

Table 5. Comparing the anterior and posterior capsule opacity of the participants in the measured intervals between the two study groups

	Grade	Total	Ketorolac group (N=46)	Control group (N=42)	p-value
Posterior capsule opacity	0	16(18.18)	12(26.09)	4(9.52)	0.002*
	I	53(60.23)	31(67.39)	22(52.38)	
	II	18(20.45)	3(6.52)	15(35.71)	
	III	1(1.14)	0	1(2.38)	
Anterior capsule opacity	I	63(71.59)	40(86.96)	23(54.76)	0.001†
	II	17(19.32)	6(13.04)	11(26.19)	
	III	7(7.95)	0	7(16.67)	
	IV	1(1.14)	0	1(2.38)	

*The results of Fisher's exact test; †The results of Chi square test; all values are reported as No.(%)

Although similar to the results of this study, this review has not considered patients with PEX and has evaluated the separate effects of the drugs, not the additional effect. Therefore, more studies are required to determine the additional effect of NSAIDs on visual acuity of patients with PEX after phacoemulsification. Another important parameter after cataract surgery is measurement of IOP that can indicate the patients' susceptibility to glaucoma (20). Glaucoma is an important comorbidity of PEX and subclinical high levels of IOP can result in increased IOP after surgery and impair the surgical outcome (20). Although the incidence of glaucoma reduces in patients with PEX after cataract surgery (21), the IOP spike is still an important complication in these patients after cataract surgery, which has been found to be associated with the severity of PEX and the pre-surgical IOP values (17). In the present study, the effect of time was significant and we noticed that the mean IOPs decreased after surgery. Vahedian and colleagues also reported significant decrease in IOP after six months (from 17.45 ± 3.32 to 12.57 ± 1.58

mmHg) (22), which are consistent with the results of the present study, although the values differed. The study by Sastry and Singal showed mean IOP of 26.23 ± 11.40 mmHg one day after cataract surgery in patients with PEX, which is close to the mean IOL of the control group in our study (27.76 ± 2.23), while Sastry and Singal did not refer to the use of postoperative eye drops. Although the mean IOP of the ketorolac users were lower one day after surgery (17.67 ± 2.68), IOP did not have a normal distribution and the medians were not different between the two groups. Comparison of the two groups in this study showed that mean IOPs were similar to pre-surgical state at the measured intervals with significantly higher mean change of IOP after one month in the group that did not receive ketorolac. These results approved the additional effect of ketorolac for reduction of IOP one month after surgery in these patients. However, more studies are required for confirming this effect, as there are various factors that can affect post-surgical IOP values, such as the diurnal IOP

variation and differences in baseline IOP of patients (22).

In the present study, we additionally measured PCO and ACO and the results showed that the frequency of both was different between the two study groups and none of the patients in ketorolac group had PCO grade III and ACO grades III and IV. Opacification of the anterior and posterior capsule is considered one of the common complications of cataract surgery that can result in secondary visual loss in the patient and thus require Nd-YAG capsulotomy or other interventions (23). The results of the present study confirmed that addition of ketorolac to steroids could reduce the incidence of high grade PCO and ACO. In a study on 13,368 patients undergoing cataract surgery showed no benefit for combination of NSAIDs and steroids to steroids alone considering the capsulotomy rates (24). But we did not evaluate this frequency to compare the results with ours. The last and the most important postoperative complication evaluated in the present study was inflammation of anterior chamber, which is of great importance in patients with PEX, supposed to have a high risk of ACI after phacoemulsification (11, 25). In the study by Sastry and Singal, 11 out of 35 patients with PEX syndrome had AC reaction 2⁺, indicative of ACI one day after surgery (17), while we observed 24 cases out of 86 patients at this time. The frequency of ACI grades were not different between the two study groups only on the day after surgery, while it was significantly different at the other intervals, in favor of ketorolac group, by both measurements (namely Flare and Cell). Coassin and colleagues, mean flare was 31% and 43% lower in the group three and seven days after surgery, respectively, in the group receiving 0.09% bromfenac in addition to 0.1% dexamethasone and 0.3% tobramycin, compared to steroids alone (14), which is in line with the results of the present study. Others have also confirmed the efficacy of NSAIDs and steroids separately

on reducing postsurgical inflammation (13, 26, 27), but have not evaluated the additional effect of NSAIDs, in combination with steroids.

The present study had few limitations. One of the limitations was the lack of patients' cooperation for follow-up examinations. Another limitation was related to the different brands of IOLs used for different patients. Also, we could not evaluate inflammation objectively by standard devices.

CONCLUSION

The results of the present study showed that addition of ketorolac to steroids resulted in a better control of inflammation after one month and reducing long-term complications, such a PCO and capsular phimosis until six months after surgery in patients with PEX undergoing phacoemulsification. Further studies with larger sample sizes and less bias are required for confirming these results.

Conflicts of Interest

There are no conflicts of interest

REFERENCES

1. Khairallah M, Kahloun R, Bourne R, Limburg H, Flaxman SR, Jonas JB, et al. Number of people blind or visually impaired by cataract worldwide and in world regions, 1990 to 2010. *Investigative ophthalmology & visual science*. 2015;56(11):6762-9.
2. Bourne RR, Stevens GA, White RA, Smith JL, Flaxman SR, Price H, et al. Causes of vision loss worldwide, 1990–2010: a systematic analysis. *The lancet global health*. 2013;1(6):e339-e49.
3. Davis G. The evolution of cataract surgery. *Missouri medicine*. 2016;113(1):58.
4. Lam D, Rao SK, Ratra V, Liu Y, Mitchell P, King J, et al. Cataract. *Nature reviews Disease primers*. 2015;1(1):1-15.
5. Stein JD. Serious adverse events after cataract surgery. *Current opinion in ophthalmology*. 2012;23(3):219.

6. Chan E, Mahroo OA, Spalton DJ. Complications of cataract surgery. *Clinical and Experimental Optometry*. 2010;93(6):379-89.
7. Fontana L, Coassin M, Iovieno A, Moramarco A, Cimino L. Cataract surgery in patients with pseudoex-foliation syndrome: current updates. *Clinical Ophthalmology (Auckland, NZ)*. 2017;11:1377.
8. Sangal N, Chen TC, editors. *Cataract surgery in pseudoexfoliation syndrome*. Seminars in ophthalmology; 2014: Taylor & Francis.
9. Sufi AR, Singh T, Mufti AA, Rather MH. Outcome of phacoemulsification in patients with and without pseudoexfoliation syndrome in Kashmir. *BMC ophthalmology*. 2012;12(1):1-5.
10. Vazquez-Ferreiro P, Carrera-Hueso FJ, Jornet JEP, Fikri-Benbrahim N, Diaz-Rey M, Sanjuan-Cerveró R. Intraoperative complications of phacoemulsification in pseudoexfoliation: Metaanalysis. *Journal of Cataract & Refractive Surgery*. 2016;42(11):1666-75.
11. Dwivedi NR, Dubey AK, ShaNKaR PR. Intraoperative and immediate postoperative outcomes of cataract surgery using phacoemulsification in eyes with and without pseudoexfoliation syndrome. *Journal of clinical and diagnostic research: JCDR*. 2014;8(12):VC01.
12. Kessel L, Tendal B, Jørgensen KJ, Erngaard D, Flesner P, Andresen JL, et al. Post-cataract prevention of inflammation and macular edema by steroid and nonsteroidal anti-inflammatory eye drops: a systematic review. *Ophthalmology*. 2014;121(10):1915-24.
13. Akbari M, Moghadam RS, Elmi R, Nosrati A, Taghiabadi E, Aghdami N. Adjunctive Tacrolimus for Herpetic Stromal Keratitis. *J Ophthalmic Vis Res* 2019;14:400–411.
14. Coassin M, Iovieno A, Soldani A, Cavuto S, Cimino L, Sartori A, et al. Bromfenac ophthalmic solution 0.09% as an adjunctive therapy to topical steroids after cataract surgery in pseudoexfoliation syndrome. *Journal of Cataract & Refractive Surgery*. 2016;42(8):1119-25.
15. Group SoUNW. Standardization of uveitis nomenclature for reporting clinical data. Results of the First International Workshop. *American journal of ophthalmology*. 2005;140(3):509-16.
16. Raj SM, Vasavada AR, Johar SK, Vasavada VA, Vasavada VA. Post-operative capsular opacification: a review. *International journal of biomedical science: IJBS*. 2007;3(4):237.
17. Sastry PV, Singal AK. Cataract surgery outcome in patients with non-glaucomatous pseudoexfoliation. *Romanian journal of ophthalmology*. 2017;61(3):196.
18. Pranathi K, Magdum RM, Maheshgauri R, Patel K, Patra S. A study of complications during cataract surgery in patients with pseudoexfoliation syndrome. *Journal of Clinical Ophthalmology and Research*. 2014;2(1):7.
19. Hoffman RS, Braga-Mele R, Donaldson K, Emerick G, Henderson B, Kahook M, et al. Cataract surgery and nonsteroidal antiinflammatory drugs. *Journal of Cataract & Refractive Surgery*. 2016;42(9):1368-79.
20. Seol BR, Shin JY, Choi S, Kang TG, Jeoung JW, Park KH. Intraocular pressure (IOP) change and frequency of IOP spike after cataract surgery in normal-tension glaucoma: a case-control study. *Journal of glaucoma*. 2019;28(3):201-6.
21. Kristianslund O, Østern AE, Råen M, Sandvik GF, Drolsum L. Does cataract surgery reduce the long-term risk of glaucoma in eyes with pseudoexfoliation syndrome? *Acta ophthalmologica*. 2016;94(3):261-5.
22. Vahedian Z, Salmanroghani R, Fakhraie G, Moghimi S, Eslami Y, Zarei R, et al. Pseudoexfoliation syndrome: Effect of

phacoemulsification on intraocular pressure and its diurnal variation. *Journal of current ophthalmology*. 2015;27(1-2):12-5.

23. Wormstone I, Wormstone Y, Smith A, Eldred J. Posterior capsule opacification: What's in the bag? *Progress in Retinal and Eye Research*. 2020;100905.

24. Hecht I, Karesvuo P, Achiron A, Elbaz U, Laine I, Tuuminen R. Anti-inflammatory medication after cataract surgery and posterior capsular opacification. *American journal of ophthalmology*. 2020;215:104-11.

25. Sufi AR, Mufti AA, Nazir N, Qureshi T, Ramzan R. Prevalence of pseudoexfoliation syndrome in patients scheduled for cataract surgery in eye camps in Kashmir. *Journal of Clinical Ophthalmology and Research*. 2014;2(3):137.

26. Maca SM, Amon M, Findl O, Kahraman G, Barisani-Asenbauer T. Efficacy and tolerability of preservative-free and preserved diclofenac and preserved ketorolac eyedrops after cataract surgery. *American journal of ophthalmology*. 2010;149(5):777-84.

27. Sahu S, Ram J, Bansal R, Pandav SS, Gupta A. Effect of topical ketorolac 0.4%, nepafenac 0.1%, and bromfenac 0.09% on postoperative inflammation using laser flare photometry in patients having phacoemulsification. *Journal of Cataract & Refractive Surgery*. 2015;41(10):2043-8.