

Case Report

Early Interceptive Orthodontic Treatments: Case Series

Ceren İlisulu 1*, Sinem Uz 1, Mine Koruyucu 1, Figen Seymen 1

1. Istanbul University, Faculty of Dentistry, Department of Pedodontics, Istanbul, Turkey, DDS PhD.

*correspondence: **Ceren İlisulu**, Istanbul University, Faculty of Dentistry, Department of Pedodontics, Istanbul, Turkey, DDS PhD. Email: cerenilisulu@gmail.com

Abstract:

Background: Early orthodontic treatment is important to guide dentitions during the development of a functional and morphological occlusion. Anterior dental crossbite and thumb sucking habits can be treated by interceptive orthodontic treatment modalities that are a method to restore a normal occlusion when a malocclusion has started to occur.

Case Presentations: The cases shown are ranging from the age of 7-9 years presenting in mixed dentition development. This article presents six cases of anterior crossbite corrected by using removal acrylic appliances with Z spring and two cases of thumb sucking habits corrected by using palatal crib. Recall examination after 6 months displayed normal occlusal relationship without any relaps.

Conclusion: Paediatric dentists have important role to diagnose malocclusions early. Early interceptive orthodontic treatment can potentially eliminate the need for future complicated and costly orthodontic treatment.

Keywords: Interceptive orthodontic; anterior crossbite; thumb sucking; palatal crib.

Introduction:

Normal development and growth of dentition is the capital issue in the progression of normal occlusion (1). The aim of early orthodontic treatment is to guide dentitions during the development of a functional and morphological occlusion (2). Early indication of developing malocclusions and interceptive orthodontic treatment procedures can eliminate future complex and costly treatment (3).

Interceptive orthodontic treatments are a method to restore a normal occlusion when a malocclusion has started to occur (3,4). During the development of the dentoskeletal complex the possible discrepancies and malposition is identified and removed through interceptive orthodontic treatments (3). Applications undertaken in interceptive orthodontics are: serial extraction, correction of developing crossbite, control of abnormal habits, space regaining, extraction of supernumerary and retained primary teeth (2).

Anterior crossbite is described as “an abnormal labiolingual relationship between one or more maxillary and mandibular anterior incisor teeth” (5). Dental crossbite is associated with tipping of a tooth or teeth, which is localized but not related to basal bone (6). Patients should display a normal skeletal pattern with abnormalities presenting one or more maxillary incisors in crossbite (7). Anterior dental crossbite should be corrected immediately to prevent abnormal enamel abrasion, anterior teeth mobility and fracture, periodontal diseases, and temporomandibular joint dysfunction (5,6,8). Treatment modalities for treatment

of anterior crossbite are: bonded resin-composite slopes, tongue blades, fixed acrylic inclined planes, reversed stainless steel crowns, removable acrylic appliances with Z springs, and Bruckl appliance (5,8).

A habit is a repetitive action that is being done automatically. Repetitive behaviors are common in infantile period and most of them are started and finished spontaneously (9). If the habit continues or increases in frequency, then adverse dentoskeletal results are observed (10). These results include, proclined maxillary and or mandibular incisors, anterior open bite, increased overjet, lingual inclination lower incisor, unilateral crossbite, deep palate, speech defect, and finger defect (10,11). Treatment options for these habits consists of direct counseling of the patient by dentist, reminder therapy, rewards concept, orthodontic appliance treatment (12).

This article describes case series in which crossbite is corrected using interceptive orthodontic treatment modalities.

Case Report:

Case 1

A male patient of 7 years was admitted to the Department of Pediatric Dentistry of Istanbul University as patient was unhappy with unaesthetic appearance of anterior teeth. A complete clinical intraoral examination revealed the permanent maxillary left and right central incisors in crossbite. Following clinical and radiographic examinations, upper removable acrylic appliances with Z springs was applied to maxillary left and right central

incisors. The crossbite was corrected in 3 months. Recall examination after 6 months displayed normal occlusal relationship without any relapse (Figure1).

Case 2

A male patient of 7 years with a concern of unaesthetic anterior tooth was referred to our clinic. On clinical examination, anterior crossbite was noticed in relation to maxillary right central incisor. The crossbite was treated with upper removable acrylic appliances with Z spring within 3 months. Z spring was activated every month. Recall examination after 6 months displayed normal occlusal relationship without any relapse (Figure 2).

Case 3

A female patient of 8 years with gingival recession was referred to our clinic. On clinical examination, anterior crossbite was observed in relation to maxillary right central incisor and gingival recession was observed due to the occlusal trauma to lower right central incisor. The crossbite was treated with upper removable acrylic appliances with Z spring within 3 months. Z spring was activated every month (Figure 3).

Case 4

A female patient of 7 years with aesthetic concerns was referred to our clinic. Intraoral examination revealed the permanent maxillary right central incisor was in crossbite. The crossbite was treated with upper removable acrylic appliances with Z spring within 3 months (Figure 4).

Case 5

A female patient of 7 years was admitted to our clinic because of thumb sucking habit. Intraoral examination revealed anterior open bite, deep palate, compensatory tongue thrust. Palatal crib was applied with glass ionomer cement by luting the appliance on upper permanent first molars. Her mother informed that she ended the habit after a month. However, the patient was informed to keep using the appliance so that there is no reversal of the habit. The patient was recalled for checkup every month and after 6 months the appliance was removed and checked for the tongue position and swallowing pattern (Figure 5).

Case 6

A male patient of 8 years with thumb sucking habit was reported to our clinic. Intraoral examination revealed anterior open bite, deep palate. Palatal crib was applied for 6 months. The patient was recalled for checkup every month (Figure 6).

Discussion:

Pediatric dentistry's one of the primary aim is helping the regular development of dentition and occlusion (6,13).

The progress of mixed dentition provides the best chance for occlusal management and interception of malocclusion (14). If not intervened, complexity may be an issue during treatment (15). Pathway of care for interception of habit and correction of anterior crossbite often requires appliances which can lead to increase of the treatment time and cost (10). This article shows how

malocclusion is corrected by using interceptive treatment modalities.

Anterior dental crossbite occurs because axis of one or more maxillary incisors that may be lingually positioned incline abnormally (16). The anterior dental crossbite may occur when primary teeth or root are retained or pulpless, odontomas is present, the arch length is not adequate, the incisor region is crowded, permanent tooth germ is displaced lingually as the primary incisor is traumatized, a repaired cleft lip is present, maxillary anterior incisors' path is lingually erupted, supernumerary anterior teeth are present, biting the upper lip has become a habit (6,8).

Anterior crossbite should be treated as soon as it is diagnosed to prevent periodontal disease, temporomandibular joint dysfunction, anterior teeth mobility and fracture and abnormal enamel abrasion (6,17). There are various methods to deal with anterior dental crossbite such as; tongue blade therapy, reverse stainless steel crowns, removable acrylic appliance with anterior Z-springs, bonded resin composite slopes, fixed orthodontic appliance (6,8).

Skeggs and Sandler stated that the correct use of fixed appliances for the treatment of anterior dental crossbite provided a more rapid treatment than the removable technique (18). Wiedel et al. reported that a successful treatment of anterior crossbite in one or more than one incisors in the mixed dentition can be achieved with both fixed or removable appliances which have similar long-term stability (19).

The oral habits can interfere with the growth and normal development of the jaws, assisting the onset of malocclusion and changes in normal swallowing and speech patterns depending on factors such as duration, frequency, intensity, and facial pattern (20). In case the habit continues during mixed dentition, it may result in dentalveolar changes for example maxillary and/or mandibular incisors may procline, or anterior open bite might develop, or overjet may increase, or unilateral crossbite and Class II malocclusion may occur (21). A variety of treatment approaches include advice, reminder therapy, rewards concept, fitting a fixed or removal appliance to interfere with the habit, or behavior modification techniques (20,16).

Palatal crib appliances are extremely effective in breaking habits. It does not only prevent the suction of the finger or pacifier but also keeps the tongue in a more retruded position, preventing its interposition between the incisors during swallowing and speech (20). Abraham et al. reported that it can act as a device for retraining the associated musculature, a mechanical restrainer and a reminder to discontinue the habit (22). Most of the studies have indicated that thumb-sucking habit was effectively ceased after palatal crib appliance treatment. This consequence might have been supported by cribs' potential ability in altering tongue posture, allowing incisors to retract and extrude (23).

CONCLUSION

The interception of the malocclusion at an early stage is effective for improving skeletal and dentoalveolar development.

Early interceptive orthodontic treatment can potentially eliminate the need for future complicated and costly orthodontic treatment. The role of pediatric dentists is crucial in determining malocclusions early.

References:

1. Ackerman JL, Proffit WR. Preventive and interceptive orthodontics: a strong theory proves weak in practice. *Angle Orthod.* 1980;50(2):76–87.
2. Muthu MS, Kumar S. *Paediatric Dentistry: Principles and Practice*. 2nd Ed., India: Elsevier Mosby. 2011, p.289-291
3. Ricketts RM, Dr. Robert M. Ricketts on early treatment: part 1 and 2. *J Clin Orthod.* 1979;8(23-8):115–27.
4. Karaikos N, Wiltshire WA, Odum O, Brothwell D, Hassard TH. Preventive and interceptive orthodontic treatment needs of an Inner-City Group of 6- and 9-year old Canadian children. *J Can Dent Assoc.* 2005;71(9):649–649e
5. Lee BD. Correction of crossbite. *Dental Clinics of North America.* 1978;22(4):647–668
6. Bayrak S, Tunc ES. Treatment of anterior dental crossbite using bonded resin-composite slopes: case reports. *European Journal of Dentistry.* 2008;2(4):303–307.
7. McEvoy SA. Rapid correction of a simple one-tooth anterior cross bite due to an over-retained primary incisor: clinical report. *Pediatric Dentistry.* 1983;5(4):280–282.
8. Prakash P, Durgesh BH. Anterior Crossbite Correction in Early Mixed Dentition Period Using Catlan's Appliance: A Case Report. *ISRN Dent.* 2011;2011:298931.
9. Shahraki N, Yassaei S, Moghadam MG. Abnormal Oral Habits. *Journal of Dentistry and Oral Hygiene.* 2012;4(2):12-15
10. Zameer M, Basheer SY, Reddy A, Kovvuru SK. A Single Versatile Appliance for Habit Interception and Crossbite Correction. *Case Reports in Dentistry,* 2015;2015: 607545.
11. Vogel LD. When children put their fingers in their mouths. Should parents and dentists care? *The New York State Dental Journal.* 1998;64(2):48–53.
12. Kamdar RJ, Al-Shahrani I. Damaging Oral Habits. *Journal of International Oral Health.* 2015;7(4):85-87
13. Al-Sehaibany F, White G. A three dimensional clinical approach for anterior crossbite treatment in early mixed dentition using an Ultrablock appliance: case report. *J Clin Pediatr Dent.* 1998;23(1):1-8.
14. Kocadereli I. Early treatment of posterior and anterior crossbite in a child with bilaterally constricted maxilla: report of case. *J Dent Child.* 1998;65(1):41-46.
15. Tse CS. Correction of single-tooth anterior crossbite. *J Clin Orthod.* 1997;31(3):188-190.
16. Borrie F, Bearn D. Early correction of anterior crossbites: a systematic review. *J Orthod.* 2011;38(3):175-184.
17. Jacobs SG. Teeth in crossbite: the role of removable appliances. *Australian Dent J.* 1989;34(1):20-28.
18. Skeggs RM, Sandler PJ. Rapid correction of anterior crossbite using a fixed appliance: A case report. *Dent Update.* 2002;29(6):299-302.
19. Wiedel AP, Bondemark L. Stability of anterior crossbite correction: A

randomized controlled trial with a 2-year follow-up. *The Angle Orthodontist*. 2015;85(2):189-195.

20. Tanaka O, Oliveira W, Galarza M, Aoki V, Bertaiolli B. Breaking the Thumb Sucking Habit: When Compliance Is Essential: Case Report. *Case Reports in Dentistry*. 2016;2016:601-615.

21. Saima S, Chaudhary S, Chaitra TR, Manuja N, Sinha A. Management of thumb sucking habit using blue grass appliance: A

Case Report. *Annals of Dental Specialty*. 2015;4(2):60-61.

22. Abraham R, Kamath G, Sodhi JS, Sodhi S, Rita C, Kalyan SS. Habit Breaking Appliance for Multiple Corrections. *Case Reports in Dentistry*. 2013;2013:647-649.

23. Madiraju GS, Harika L. Effectiveness of appliance therapy in reducing overjet and open bite associated with thumb sucking habit. *Minerva Stomatologica*. 2011;60(7):333-338.

Tables and Charts:

Figure 1: A 7 years old male patient with anterior dental crossbite (a); removable acrylic appliances with Z spring (b); intraoral clinical photograph with removable acrylic appliances with Z spring (c); 3 months after treatment (d).

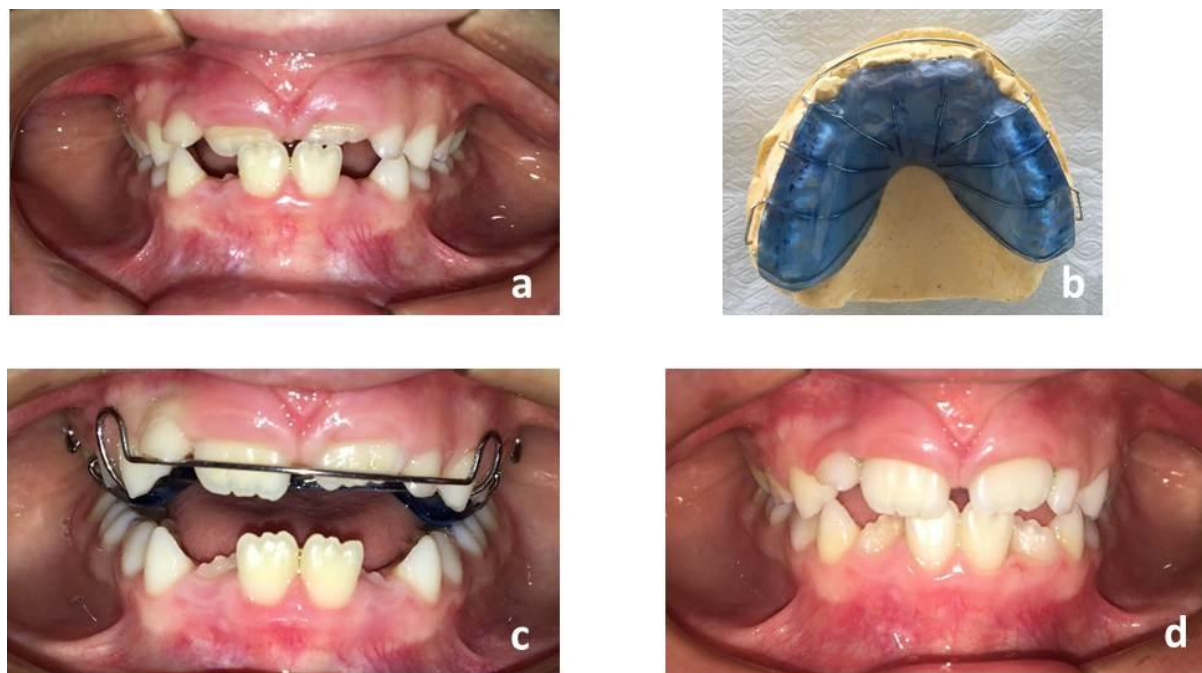


Figure 2: Intraoral clinical photograph with 7 years old male patient (a); 3 months after treatment (b).

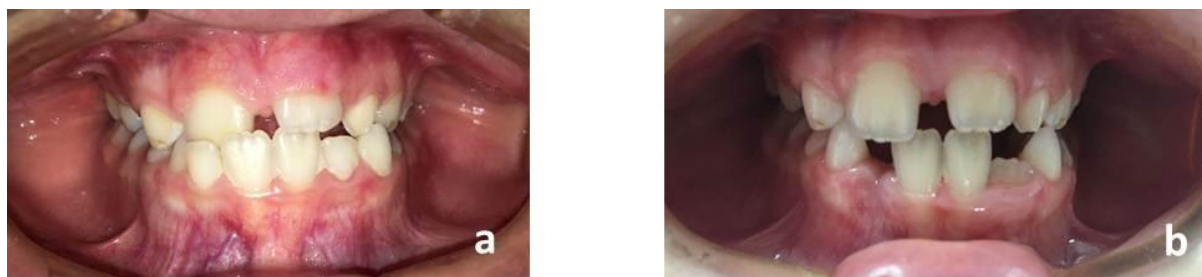


Figure 3: Intraoral clinical photograph with 8 years old female patient (a); 3 months after treatment (b).

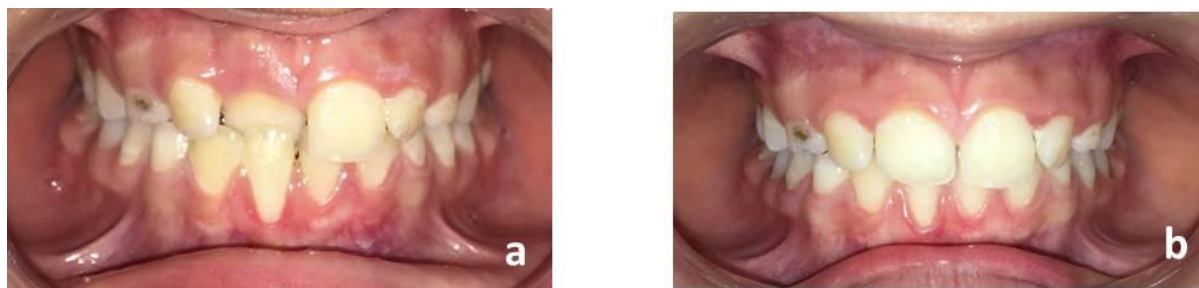


Figure 4: Intraoral clinical photograph with 7 years old female patient (a); 3 months after treatment (b).

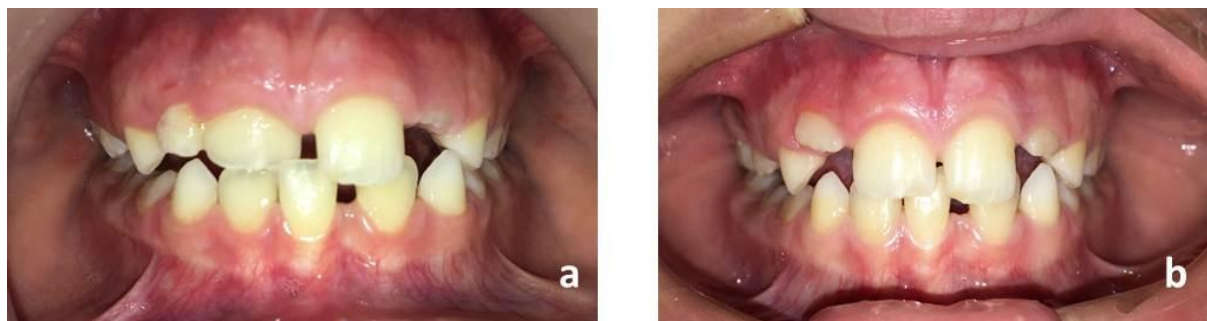


Figure 5: A 7 years old female patient's intraoral clinical photographs with thumb sucking (a); Palatal crib appliance (b); 3 months after treatment (c); 6 months after treatment (d).

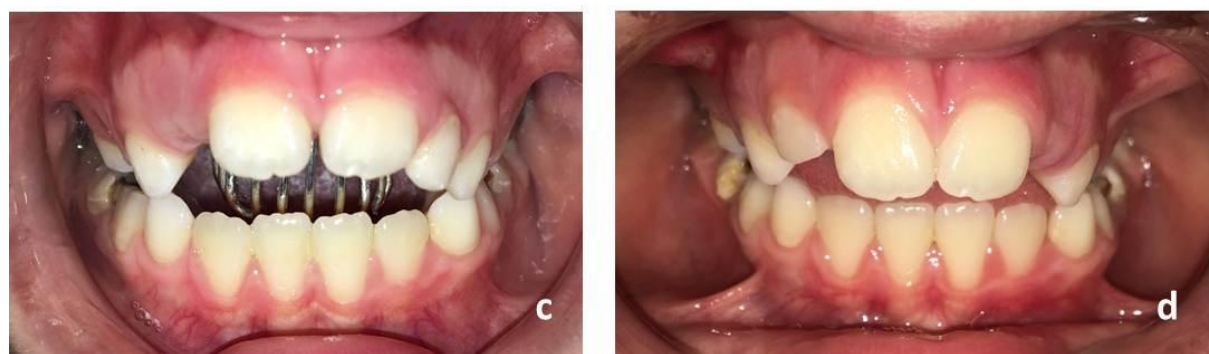
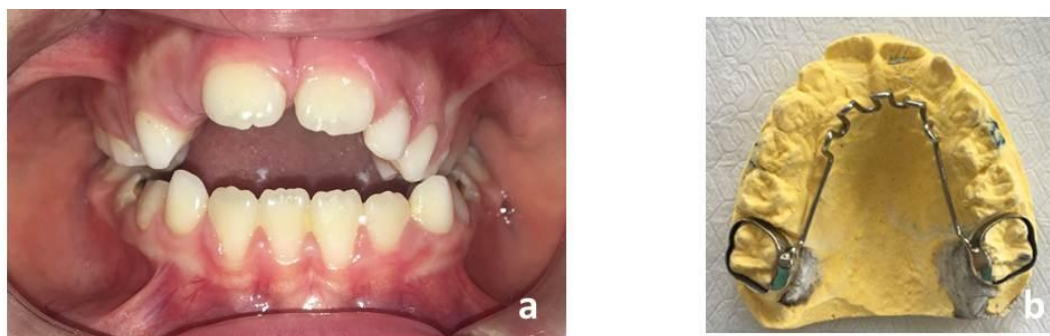


Figure 6: A 8 years old male patient's intraoral clinical photographs with thumb sucking (a); 3 months after treatment (b); 6 months after treatment (c).

