

Case Report

Fetal Coarctation of the Aorta Successfully Repaired in the Neonatal Period, a Case Report and Review of Literature

Alireza Golbabaee¹, Ehsan Aghaei Moghaddam², Mohammad Taghi Majnoun², Ali Mirabi^{3*}

1. Department of Pediatrics cardiology, Faculty of Medicine, Mazandaran University of Medical Sciences, Sari, Iran
2. Department of Pediatrics cardiology, Faculty of Medicine, Tehran University of Medical Sciences, Tehran, Iran
3. Medical Student, Student Research Committee, Mazandaran University of Medical Sciences, Sari, Iran.

*correspondence: **Ali Mirabi**, Medical Student, Student Research Committee, Mazandaran University of Medical Sciences, Sari, Iran. alimir7292@gmail.com

Abstract

Coarctation of the aorta is one of the most difficult conditions to diagnose during fetal life with affecting with a frequency of approximately 5-8% of live births with congenital heart disease. We would like to report a case of coarctation of the aorta diagnosed prenatally at 28 weeks' gestation. There were evidences of right ventricular and atrial enlargements, significant aortic stenosis, antegrade and retrograde flow in proximal part of descending aorta at fetal echocardiography. Since it was not appropriate time for abortion, the pregnancy was monitored and continued to termination. Surgical relief of the aortic obstruction was done in the day 20 of birth. The neonate was surgically treated successfully. Prenatal diagnosis of coarctation of the aorta is potentially life-saving and can improve the outcomes of operative conditions in infants preparing for surgery. Early detection and surgically repair of Coarctation of the aorta can significantly improve survival rate of affected neonates.

Key words: Coarctation of the Aorta, congenital heart disease, fetal echocardiography, prenatal diagnosis

Introduction:

Coarctation of the aorta (CoA) is one of the most common ductal-dependent forms of congenital heart defects accounting for 5 to 8% of children with congenital heart disease (CHD) (1). CoA most often goes misdiagnosed not only during fetal life but also during the neonatal period. An estimated Sixty to eighty percent of CoA are not diagnosed prenatally. Prenatal diagnosis of CoA is important as it may reduce the risk of morbidity and mortality and improve

neonatal survival outcomes (2-4). Disproportion in ventricular size (right ventricle being larger than the left ventricle), discrepancy in great artery size (the pulmonary artery being larger than the aorta), and the absolute diameter measurement of the aortic isthmus are some prenatal features consistent with CoA (5, 6). Here we reported a case of CoA with diagnosed at 28 weeks' gestational age on routine fetal echocardiographic examination in a 34-year-old diabetic woman finally treated

successfully with surgical repair in the day 20 of birth.

Case presentation:

A 34-year-old woman (gravida 1, Para 0, Abortus 0) known case of diabetic mellitus was referred for fetal echocardiographic examination at 28 weeks' gestational age due to the routine medical assessments. There were not past medical history of any underlying diseases such as hypertension. Family history of congenital heart disease was negative.

There were right ventricular and atrial enlargements at fetal echocardiography (Figure 1). Echocardiographic evidence of significant aortic stenosis, antegrade and retrograde flow in proximal part of descending aorta (DAO) in aortic arch view fetal echocardiography were seen (Figure 2 and 3). There was CoA in suprasternal notch view in transthoracic echocardiography (figure 4). On color Doppler imaging, flow acceleration in stenotic portion of descending aorta was noted (Figure 5). According to the findings, the diagnosis of coarctation of the aorta was suggested for the fetus. Since it was not appropriate time for abortion, the pregnancy was monitored and continued to termination. After delivery, there were pathological cardiovascular findings of right ventricular (RV) failure. Doppler spectral echocardiography showed saw tooth appearance (Figure 6). Computed tomography (CT) scan also revealed CoA in neonate (Figure 7).

Surgical relief of the aortic obstruction was done in the day 20 of birth. No immediate

complications were seen during surgical operation and the newborn was in stable condition. Imaging of suprasternal view (posterior repair of coarctation) showed no significant narrowing of DAO in neonate after surgery (Figure 8). After the postoperative course, the newborn and the woman were in good conditions. The patient is being regular follow up with pediatric cardiologist and is in good health.

Discussion:

CoA is one of the most poorly detected lesions at routine prenatal and postnatal screening and is life threatening cardiovascular condition if undiagnosed in the early neonatal period. The incidence of CoA is approximately 4-5 per 100 live births with congenital heart defects (7, 8). CoA may occur as an isolated defect or in combination with bicuspid aortic valve and ventricular septal defect or other associated cardiovascular lesions (9).

Diagnosis of CoA remains challenging. Prenatal diagnosis of CoA can be difficult to make even in the best centers. CoA is a congenital vascular anomaly characterized by narrowing of the aorta, stricture of the distal aortic arch, and isthmus narrowing between the bifurcation of the left subclavian artery (5, 10). Prenatal diagnosis of CoA is associated with higher survival rate and better preoperative clinical outcome than postnatal diagnosis (11). In our case, the diagnosis of CoA was suggested according to the dominance of right articular and ventricular structures, significant aortic stenosis, flow acceleration in stenotic portion and antegrade and retrograde flow in

proximal part of descending aorta in fetal imaging evaluations.

The exact mechanism of CoA is not clearly understood. Abnormal preductal flow or abnormal angle between the ductus and aorta with increasing right-to-left ductal flow and decreasing isthmic flow are the most commonly hemodynamic and ectopic ductal tissue theories in the pathogenesis of CoA (12). Fetal CoA has no significant effect on intrauterine hemodynamics since the right ventricle via the ductus arteriosus mainly supplies the descending aorta. Left ventricle to right ventricle size discrepancy and additionally great vessel disproportion are findings in prenatal screening which will be potentially helpful to distinguish the true CoA requiring neonatal cardiac surgery (13, 14).

The clinical manifestations of CoA in infants are typically quite apparent with pallor, grunting, shock, and decreased lower extremity pulses with lag between upper and lower extremity pulses (15). In our newborn case, there were cardiovascular pathology of heart RV failure including tachypnea, tachycardia, pallor, respiratory distress, grunting and feeding difficulties.

Imaging and hemodynamic evaluations for coarctation anatomy with transthoracic Doppler echocardiography in suspected CoA is best done via the suprasternal notch view and should include continuous wave Doppler assessment of the distal aortic arch and isthmus. Transthoracic echocardiography is the most important diagnostic test for evaluation of both the anatomy and the haemodynamic effects of CoA (16, 17). In our patient, CoA manifested with signs of CoA in

suprasternal view in transthoracic echocardiography during fetal life.

Newborns presenting with coarctation may have associated intracardiac shunting, patency of the arterial duct, depressed ventricular function, and/or elevation of right ventricular pressure. In newborns with aortic coarctation, spectral Doppler is the primary tool used for identification of additional left-sided obstructive lesions. Approximately 25% of infants with CoA were diagnosed with mitral stenosis and/or aortic stenosis during the period of follow-up (18). In our case there was saw tooth appearance in Doppler spectral echocardiography in the newborn and CoA was also obvious in CT scan.

Surgical treatment of aortic coarctation allows to reach adult age and also improves the reproductive capacity of women (19). Patients with successfully treated coarctation often continue to have systemic arterial hypertension both at rest and with exercise despite the absence of any residual coarctation due to various potential mechanisms including resetting the renin-angiotensin system (RAS), impaired small-resistance-vessel reactivity and abnormal aortic distensibility (20). Our case was successfully treated surgically and at present is at good condition and being regular follow up.

Conclusion:

Our study showed that prenatal diagnosis of coarctation of the aorta is potentially life-saving and can improve the outcome of operative conditions in infants preparing for surgery. Early detection and surgically repair

of CoA can significantly improve survival rate of affected neonates.

Conflict of interest:

Authors declare no conflict of interest.

References:

1. Lannering K, Bartos M, Mellander M. Late diagnosis of coarctation despite prenatal ultrasound and postnatal pulse oximetry. *Pediatrics*. 2015;136(2):e406-e12.
2. Holland B, Myers J, Woods C. Prenatal diagnosis of critical congenital heart disease reduces risk of death from cardiovascular compromise prior to planned neonatal cardiac surgery: a meta-analysis. *Ultrasound in Obstetrics & Gynecology*. 2015;45(6):631-8.
3. Mellander M, Sunnegårdh J. Failure to diagnose critical heart malformations in newborns before discharge—an increasing problem? *Acta Paediatrica*. 2006;95(4):407-13.
4. Chang R-KR, Gurvitz M, Rodriguez S. Missed diagnosis of critical congenital heart disease. *Archives of pediatrics & adolescent medicine*. 2008;162(10):969-74.
5. Sharland GK, Chan K-Y, Allan LD. Coarctation of the aorta: difficulties in prenatal diagnosis. *Heart*. 1994;71(1):70-5.
6. Hornberger LK, Weintraub RG, Pesonen E, Murillo-Olivas A, Simpson IA, Sahn C, et al. Echocardiographic study of the morphology and growth of the aortic arch in the human fetus. Observations related to the prenatal diagnosis of coarctation. *Circulation*. 1992;86(3):741-7.
7. Wren C, Reinhardt Z, Khawaja K. Twenty-year trends in diagnosis of life-

threatening neonatal cardiovascular malformations. *Archives of Disease in Childhood-Fetal and Neonatal Edition*. 2008;93(1):F33-F5.

8. Reller MD, Strickland MJ, Riehle-Colarusso T, Mahle WT, Correa A. Prevalence of congenital heart defects in metropolitan Atlanta, 1998-2005. *The Journal of pediatrics*. 2008;153(6):807-13.
9. Isomatsu Y, Imai Y, Shin'oka T, Aoki M, Sato K. Coarctation of the aorta and ventricular septal defect: should we perform a single-stage repair? *The Journal of thoracic and cardiovascular surgery*. 2001;122(3):524-8.
10. Dijkema EJ, Leiner T, Grotenhuis HB. Diagnosis, imaging and clinical management of aortic coarctation. *Heart*. 2017;heartjnl-2017-311173.
11. Franklin O, Burch M, Manning N, Sleeman K, Gould S, Archer N. Prenatal diagnosis of coarctation of the aorta improves survival and reduces morbidity. *Heart*. 2002;87(1):67-9.
12. Roos-Hesselink J, Schölzel B, Heijdra R, Spitaels S, Meijboom F, Boersma E, et al. Aortic valve and aortic arch pathology after coarctation repair. *Heart*. 2003;89(9):1074-7.
13. Quartermain MD, Cohen MS, Dominguez TE, Tian Z, Donaghue DD, Rychik J. Left ventricle to right ventricle size discrepancy in the fetus: the presence of critical congenital heart disease can be reliably predicted. *Journal of the American Society of Echocardiography*. 2009;22(11):1296-301.
14. Slodki M, Rychik J, Moszura T, Janiak K, Respondek-Liberska M. Measurement of the Great Vessels in the

Mediastinum Could Help Distinguish True From False-Positive Coarctation of the Aorta in the Third Trimester. *Journal of Ultrasound in Medicine*. 2009;28(10):1313-7.

15. Boris JR. Primary-care management of patients with coarctation of the aorta. *Cardiology in the Young*. 2016;26(8):1537-42.

16. Aboulhosn J, Child JS. Left ventricular outflow obstruction: subaortic stenosis, bicuspid aortic valve, supraaortic stenosis, and coarctation of the aorta. *Circulation*. 2006;114(22):2412-22.

17. Erbel R, Bednarczyk I, Pop T, Todt M, Henrichs K, Brunier A, et al. Detection of dissection of the aortic intima and media after angioplasty of coarctation of the aorta. An angiographic, computer tomographic, and echocardiographic comparative study. *Circulation*. 1990;81(3):805-14.

18. Levine JC, Sanders SP, Colan SD, Jonas RA, Spevak PJ. The risk of having additional obstructive lesions in neonatal coarctation of the aorta. *Cardiology in the young*. 2001;11(1):44-53.

19. Dessole S, D'Antona D, Ambrosini G, Fadda MC, Capobianco G. Pregnancy and delivery in young woman affected by isthmus coarctation of the aorta. *Archives of gynecology and obstetrics*. 2000;263(3):145-7.

20. O'sullivan J, Derrick G, Darnell R. Prevalence of hypertension in children after early repair of coarctation of the aorta: a cohort study using casual and 24 hour blood pressure measurement. *Heart*. 2002;88(2):163-6.

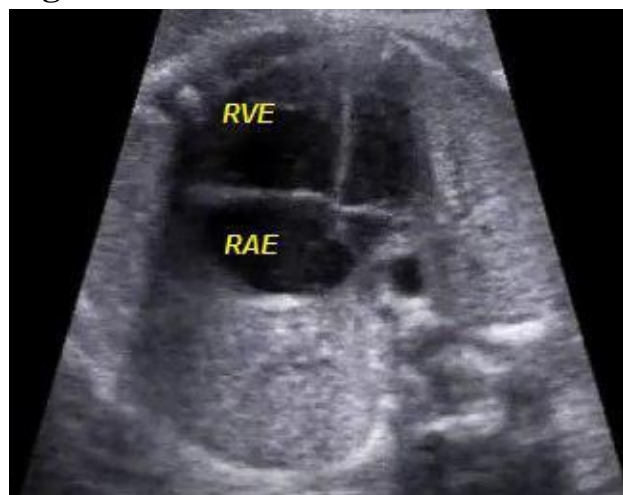Figures:

Figure 1: four-chamber view in fetal echocardiography showed right ventricular enlargement (RVE) and right articular enlargement (RAE).

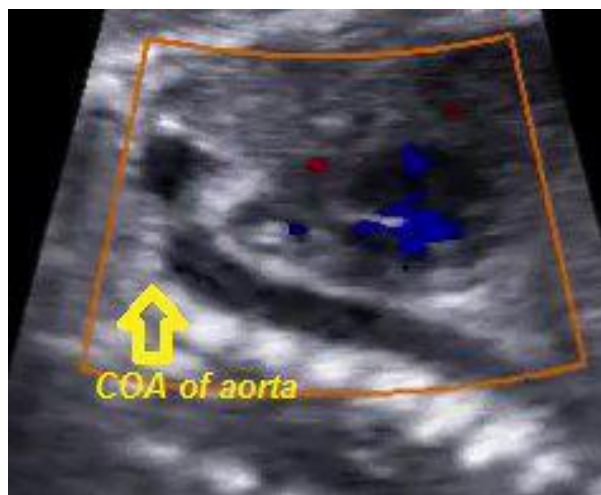


Figure 2: Aortic arch view in fetal echocardiography showed significant stenosis in proximal part of descending aorta (DAO).

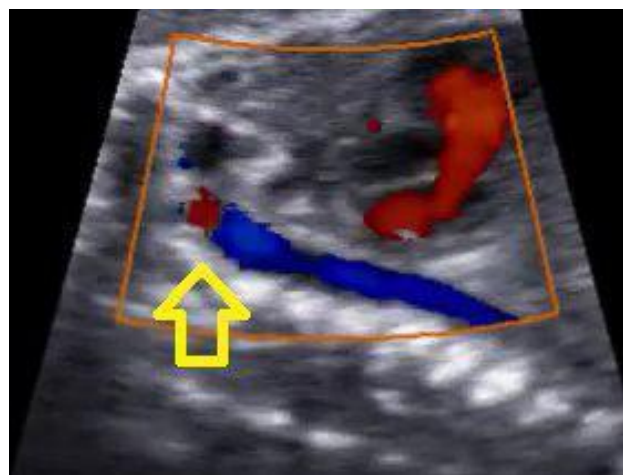


Figure 3: Aortic arch view in fetal echocardiography showed antegrade and retrograde flow in DAO proximal.

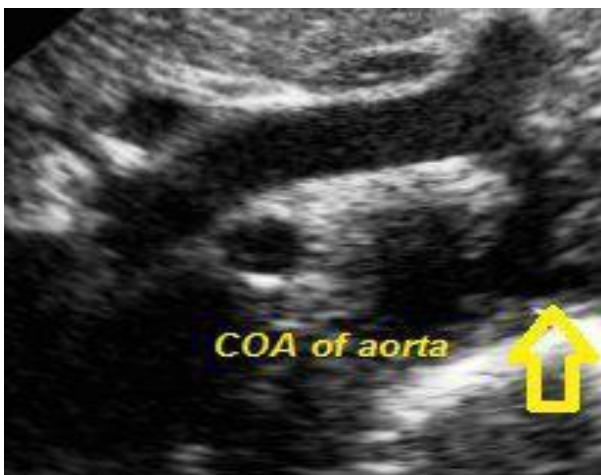

Figure 4: Suprasternal notch view in transthoracic echocardiography showed coarctation of the aorta (CoA).

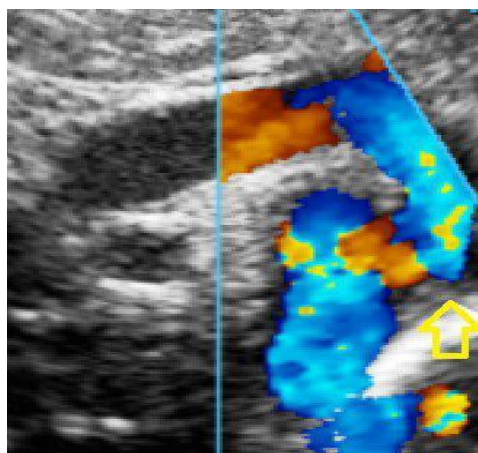


Figure 5: color Doppler echocardiography showed flow acceleration in stenotic portion of DAO.

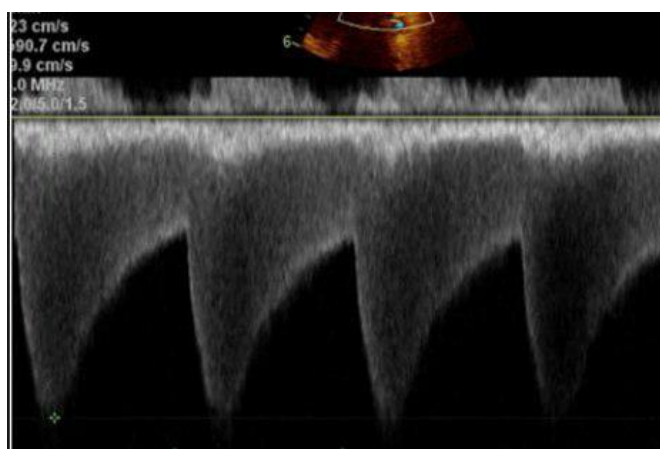


Figure 6: Doppler spectral echocardiography showed saw tooth appearance in neonate.

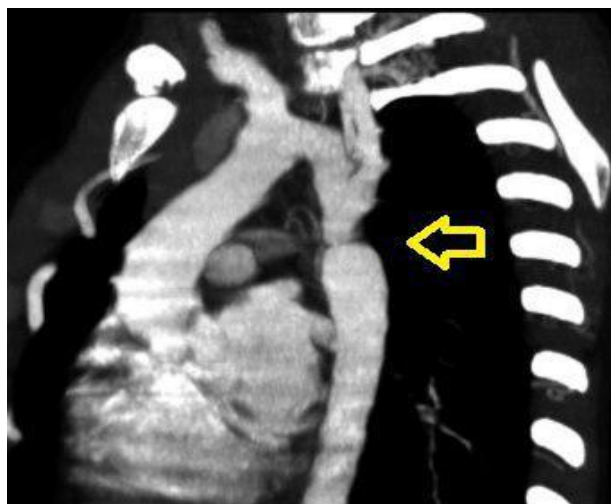

Figure 7: computed tomography (CT) scan in sagittal view showed CoA in neonate.

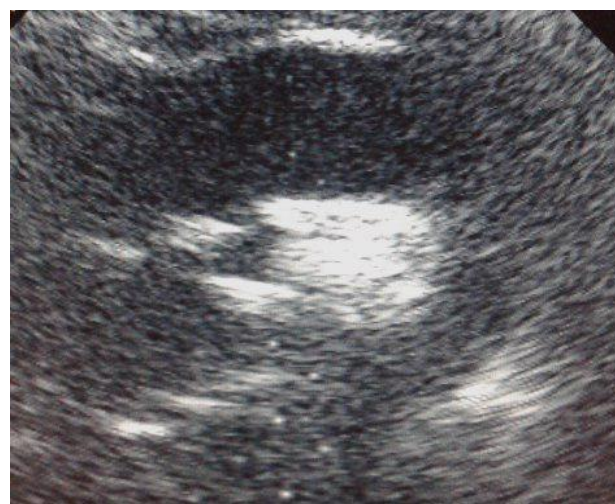

Figure 8: Suprasternal view (posterior repair of coarctation) showed no significant narrowing of DAO in neonate.