

## Original article

# Incidence of Pericardial Effusion Post Pericardiotomy Diagnosis, Intervention and Treatment

Moh, Harbe Khassawneh 1, Zyad Abdelrazzaq Alfawaeer2\*, Dawood Moh, D Attallah2

1. Surgery fellowship, Department of cardiac Surgery, Amman, Jordan, queen alia heart institute.
2. MD, Intervention cardiologist specialist, Division of Cardiology, Department of Medicine, Amman, Jordan queen alia heart institute.

\*Correspondence: **Zyad abdelrazzaq alfawaeer**, MD, Intervention cardiologist specialist, Division of Cardiology, Department of Medicine, Amman, Jordan queen alia heart institute. Email: Dr.ziead75@gmail.com

## Abstract:

**Introduction:** Pericardial effusion is the presence of an abnormal amount of and/or an abnormal character to fluid in the pericardial space. It can be caused by a variety of local and systemic disorders, or it may be idiopathic. The objectives of this study were to review recent experience at our institution in the management of pericardial effusion, to determine modalities and outcomes of treatment. The aim of this study is to evaluate the incidence of early and late (>30 days) development of pericardial effusion. Between April 2015 and April 2017.

**Method:** pericardial effusion occurrence was assessed in 358 adult who underwent cardiac surgery for (CABG, valvular surgery, or combined of both) by serial echocardiography.

**Findings:** The prevalence of PE was about 3% for all cardiac surgeries. Symptoms Clinical manifestations were observed and response to different therapies was analyzed. 358 patients with a mean age of  $60.4 \pm 9.2$  years undergoing coronary artery bypass grafting alone or combined with valve surgery. Large pericardial effusions develop in 30% of patients after cardiac surgery, and reach their maximum size after 10 days, with tamponade in 0.1%.

**Conclusion:** In our analysis, pericardial effusion occurred in 3% of patients, and symptoms were nonspecific. Several factors, mainly related to preoperative characteristics and type of operation, predispose patients to effusion. Echocardiography-guided pericardiocentesis is effective and safe in these patient. }

**Keywords:** pericardial tamponad, Pericardial Effusion, chest X-ray, Echocardiograph.

## Introduction:

Irrespective of many recent improvements in intraoperative management and postoperative care, late pericardial effusions remain an important reason behind source of morbidity after cardiac surgery. Pericardial effusions may postpone recovery and can be life threatening when tamponade leads to hemodynamic instability (1). In the modern

era, because of widespread use of serious anticoagulation and increased difficulty of operations, the occurrence of effusion could be higher especially in valve surgery (2). Therefore it is important to obtain updated information about the symptoms risk factors of pericardial effusion in order to arrange

policy at our institute for its prevention, diagnosis, and treatment (3-6).

Echocardiographic and Doppler evaluations before and 7, 10 days after cardiac surgery; With echocardiographic and Doppler follow-up Of patients with moderate or large pericardial effusion after operation Echo-Doppler imaging is useful for the evaluation of pericardial fluid accumulations after cardiac surgery. It can identify effusions that herald cardiac tamponade (4).

Type of cardiac surgery, mechanical or bioprosthetic valve, use of anticoagulant, duration of chest tube insertion, role of NSAID, colchicine in pericardial effusion. Setting-Patients Undergoing cardiac surgery (CABG, valve replacement) at tertiary Centre. Patients 358 consecutive.

## Methods:

Three hundred fifty eight successive cardiac patients (220 men; 110 women) were studied at queen alia heart institute to determine the incidence and natural history of pericardial effusion occurring 10, and 20 days after pericardiotomy regarding valves and CABG surgery between 12march 2015 to 14 April 2017. Twenty three of the consecutive patient were excluded from the study because of (bleeding or cardiac tamponade requiring earlier operation (< 2 days). Seventeen of these patients had undergone coronary artery bypass grafting and six had valve replacement. Thirty patients got pericardial effusions 5 days after surgery post removal of drains (mediastinal and pericardial) 13 men and 7 women. And on the tenth postoperative day about 45 patient developed pericardial effusion. In

twenty-five of these patients, effusions reached their maximum size by postoperative day 12, we followed-up 75 patients with effusions, 40% were followed to complete A particular pattern of effusion behavior were noticed in most resolving effusions. Most of echo-free space of pericardial effusion became subsided gradually in size and density which have been motionless, resumed its normal systolic anterior motion. One patient developed cardiac tamponade on postoperative day 15. All of us conclude that pericardial effusion occurs commonly after heart surgery. Main outcomes measure. Size and site of pericardial effusion evaluated by cross sectional echocardiography and, signs of cardiac tamponade detected.

**Echocardiography:** is the technique of choice for the medical diagnosis of pericardial effusion. Discover as little as 12-15 to 20 ml of pericardial fluid. Also, revealed that accurate quantification of pericardial effusion could be derived from M setting echocardiograms which pointed out by Cheitlin MD, Alpert JS, Armstrong WF (5, 6). The relationship for moderate-sized effusions was best, while that for small or large effusions was less accurate. Emphasized that lack of side effects and reproducibility of results make echocardiography ideally suitable for study. Also, for critically ill patients became possible. Pericardial effusion is very common after heart procedure surgery. Despite the high incidence of effusion, the clinical method of this problem remains controversial. Retrospective studies defining the course and outcome of postoperative pericardial effusion have not recently been

done. Once pericardial effusion is documented, serial echocardiographic studies are frequently performed (3) at considerable expense.

**Statistical analysis:** Groups were compared by  $\chi^2$  analysis; results were regarded as significant when  $P < 0.05$ .

## Findings:

Three hundred five eight successive patients who underwent cardiac surgery at queen Alia hospital institute during March 2015-2017 were studied. There have been 230 (31%) men and 15 (0.5%) women, ranging in a group from 20 to sixty five years (mean 49).

Operations performed were coronary artery in 200 patients, valve replacement in 100, coronary artery bypass with valve replacement in 30, aortic and mitral valve replacement in 3, and repair of an atrial septal defect in two. M mode echocardiograms were obtained in all of the patients before surgery. As well as in addition, the 3rd, fifth and tenth postoperative days.

Studies were performed on postoperative 5, 7 days in 209 patients (62%) post chest drains removed. Outpatient follow-up studies were performed days after surgery in 126 patients (37%). Echoview was used for all. All echocardiograms were registered by two experienced echocardiographers who used standard techniques. On serial studies, an attempt was made to keep patient position and transducer orientation regular to reduce positional variation in effusion size. Pericardial effusion is not a rare complication of cardiac surgery 2 though it is generally reversible and not life threatening, it may sometimes evolve towards cardiac tamponade.

Echocardiography is the best diagnostic technique (5). Cross sectional studies

showed that postoperative, pericardial effusions are often diffuse and that even small amounts of fluid in the posteromedial wall, posterolateral wall, or along the free wall of the right atrium and right ventricle can considerably disturb the heart function (6-9).

We studied the postoperative accumulation of fluid in the pericardium; its relations with type of cardiac surgery, and the characteristics. Symptoms, natural history of effusions leading to cardiac tamponade.

Identify the Effusion which resolved after left thoracocentesis for pleural effusion in 3 patients (1%); 67 patients (20%) were resolved spontaneously. In 7 situations (0.5%) developed recurrent effusion required drainage after initial pericardiocentesis. Independent risk factors for effusion renal impairment, urgency of operation, heart procedure other than heart artery bypass grafting, and prolonged cardiopulmonary bypass

CABG, coronary artery bypass grafting. \* $P <$  compared with valve replacement group another group.  $P$  value  $<$  compared with valve replacement group and other group

Table 1 shows the incidence and size of pericardial effusions in the study population and their distribution according to the type of operation.

Effusion was detected in 235(85%) of the 335 patients and was more often associated with coronary artery bypass grafting(29%) than with valve replacement (22%) or other types of surgery ( 5%). It was classified as small in 200 (75% of cases with effusion), moderate in 70 (24%), and large in 15 (15%). Small pericardial effusions were slightly more frequent after CABG (37% of cases with effusion in this group) than valve replacement (30%). For moderate effusions the reverse was true. All these differences were statistically significant

As mentioned before, we made no attempt to influence the postoperative management of

these patients. The attending surgeons made the restorative decisions based on their own clinical viewpoint.

Nonetheless, we recorded the use of all medications that may have afflicted the dimensions of how big is pericardial effusion. These kinds included aspirin and non-steroidal anti-inflammatory drugs and steroid, colchicine drugs either alone or in combination (3, 4). It should be noted that some of these medications were given for reasons other than for treatment of pericardial effusion.

For instance, aspirin was routinely administered to most patients who underwent aortic valve replacement. Of the 100 patients with pericardial effusion, 30 received one of the aforementioned drugs. The duration of administration varied widely. However, in 20 of the 30 patients, therapy was started while the effusion was resolving (decreasing in size). In other patients the effusion peaked in size after therapy had already begun. Five of the 19 patients without pericardial effusion were also treated. The role of treatment and its relationship to the peak size of pericardial effusion.

Anterior and posterior effusions were measured as the maximal diastolic separation between pericardium and epicardium recorded at the level of the tip of the mitral valve. Mode of resolution. (75%) of effusions had the appearance of an echo-free space. The areas of the remaining, (25%) were more echo-dense than the left ventricular blood pool, but often less dense than the left ventricular posterior wall. On subsequent studies an additional 45 effusions became echo-dense. The echo-dense quality first appeared in 21 patients on postoperative day 7. In 26 on postoperative day 10, in 12 on postoperative day 10. Care was taken to maintain echogenicity of the left ventricular

posterior wall on serial studies. Therefore, comparison between its echogenicity and that of the pericardial effusion (both in absolute and relative terms) was accurate creating echodensity artificially, gain control settings were similar on sequential studies.

Total effusion (sum of the anterior and posterior) was categorized as small (1 to 3mm), moderate (30 to 50 mm), or large (50 mm or more). Although the echocardiograms were available to the patients' physicians, no attempt was made to influence postoperative management.

## Discussion:

Reapproximation of the pericardium after cardiac procedure (CABG versus valve replacement) may raise the amenability to cardiac tamponade (4). Nevertheless closure of the pericardium reduces postoperative blood and protects the cardiovascular system when sternotomy has to be repeated it also increase risk of tamponade. Two Doppler examination was useful in the diagnosis of cardiac tamponade. Most patients with tamponade and none of those with average effusion had right atrial or right ventricular collapse or inferior vena cava distention.

Pericardial effusion is common after cardiac surgery. In a study of 40 randomly selected pediatric patients (5, 6) found a 53% incidence of postoperative pericardial effusion. Nineteen of twenty one effusions occurred by day 5. Studies beyond day 10 were not reported; all patients showed resolving effusions on the last day of study. These patients did as well as those without effusions at discharge. We found that virtually all effusions were present by, the

fifth postoperative day. Therefore, in a patient without an effusion by day 5, further echocardiograms seem is not a must unless the patient is symptomatic (7).

In our group of 122 patients, 85% developed effusion. We realize that the size of effusion may have no bearing on the clinical course in these patients. A small effusion may cause tamponade (8) and a moderate or large effusion may produce no symptoms and therefore may not be suspected. In fact, many of our patients with significant effusions were discharged 8 to 10 days after surgery.

This study did not attempt to define the efficacy of treatment for postoperative pericardial effusion. Although we noted no difference in treated versus untreated patients, this problem was not approached systematically. Different drugs were used for varying periods, and were used to treat different clinical problems. Before the exact effect with the various drugs can be established, a detailed, prospective, randomized study needs to be undertaken

## Conclusion

In summary, we have found that pericardial effusion after cardiac surgery is extremely common, but that associated complications are rare. By 20 days after surgery, most effusions are nearly or completely resolved (8-10). We conclude that prolonged hospital stays or the performance of serial echocardiograms for clinically uncomplicated pericardial effusion is both costly and unnecessary and should be avoided.

Diffuse effusion tended to be associated with control device replacement (8% of postoperative effusions) and loculated effusion were more prevalent more usually after heart artery bypass grafting (6% of postoperative effusions). Fifty percent the patients who is a cardiac artery bypass grafting just had an anterior effusion whereas patients who experienced valve replacement were more likely to have a postero-lateral effusion. Inflammation or bleeding caused fluid to accumulate posteriorly and side to side although loculated anterior effusions were more common after coronary artery bypass, this may be because the internal thoracic wall bleeds more frequently during schedule internal mammary harvesting.

## References:

1. Maisch B. Pericardial diseases, with a focus on etiology, pathogenesis, pathophysiology, new diagnostic imaging methods, and treatment. *Curr Opin Cardiol.* 1994 May. 9(3):379-88. [Medline].
2. Weitzman LB, Tinker WP, Kronzon I, Cohen ML, Glassman E, Spencer FC. The incidence and natural history of pericardial effusion after cardiac surgery--an echocardiographic study. *Circulation.* 1984;69(3):506-11. [PubMed]
3. Artom G, Koren-Morag N, Spodick DH, et al. Pretreatment with corticosteroids attenuates the efficacy of colchicine in preventing recurrent pericarditis: a multi-centre all-case analysis. *Eur Heart J.* 2005 Apr. 26(7):723-7. [Medline]



4. Beland MJ, Paquet M, Gibbons JE, Tchervenkov CI, Dobell AR. Pericardial effusion after cardiac surgery in adult and effects of aspirin for prevention. *Am J Cardiol.* 1990;65(18):1238–41. [PubMed]
5. Guideline] Cheitlin MD, Alpert JS, Armstrong WF. ACC/AHA Guidelines for the Clinical Application of Echocardiography. A report of the American College of Cardiology/American Heart Association Task Force on Practice Guidelines (Committee on Clinical Application of Echocardiography). Developed in coll. *Circulation.* 1997 Mar 18. 95(6):1686-744. [Medline].
6. Chong HH, Plotnick GD. Pericardial effusion and tamponade: evaluation, imaging modalities, and management. *Compr Ther.* 1995 Jul. 21(7):378-85. [Medline].
7. Merce J, Sagrista-Sauleda J, Permanyer-Miralda G, Evangelista A, Soler-Soler J. Correlation between clinical and Doppler echocardiographic findings in patients with moderate and large pericardial effusion: implications for the diagnosis of cardiac tamponade. *Am Heart J.* 1999 Oct. 138(4 Pt 1):759-64. [Medline].
8. Kuvin JT, Harati NA, Pandian NG, Bojar RM, Khabbaz KR. Postoperative cardiac tamponade in the modern surgical era. *Ann Thorac Surg.* 2002 Oct. 74(4):1148-53. [Medline]. Ben-Horin S,
9. Andreasen JJ, Sorensen GV, Abrahamsen ER, et al. Early chest tube removal following cardiac surgery is associated with pleural and/or pericardial effusions requiring invasive treatment. *Eur J Cardiothorac Surg.* 2016 Jan. 49(1):288-92. [Medline]
10. Sagrista-Sauleda J, Merce AS, Soler-Soler J. Diagnosis and management of pericardial effusion. *World J Cardiol.* 2011 May 26. 3(5):135-43. [Medline].

## Table and Charts:

**Table 1.** Incidence and size of pericardial effusion

<b>Total no. 385 patient</b>	<b>CABG</b>	<b>VALVE</b>	<b>COMBINED</b>	<b>OTHERS</b>
<b>Type of effusion</b>	335	200	100	30
<b>Small Effusion Less than 3 cm thickness</b>	200	65	70	18
<b>moderate effusion between 3-5 cm</b>	70	8	10	6
<b>Large effusion More than 5cm</b>	15	2	5	1

**Table 2.** Effects of drug treatment

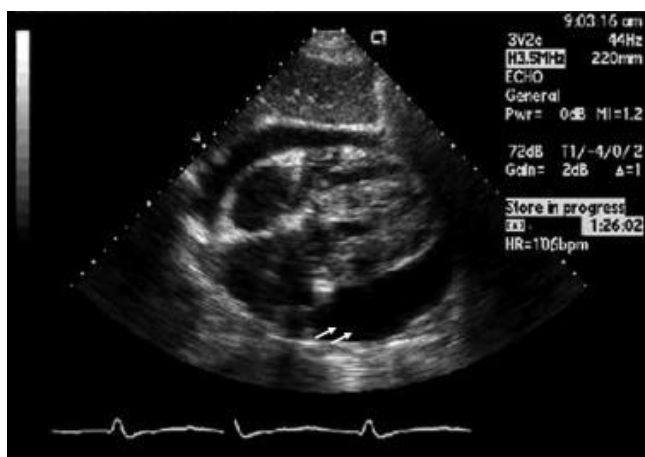
<b>Drug name</b>	<b>Total no. of patient</b>	<b>Treatment started before pericardial effusion</b>	<b>Treatment after pericardial effusion</b>
aspirin	30	20	10
Indomethacin	100	0	100
prednisolone	10	5	3
colchicine	5	0	1

All values indicate number of patients.

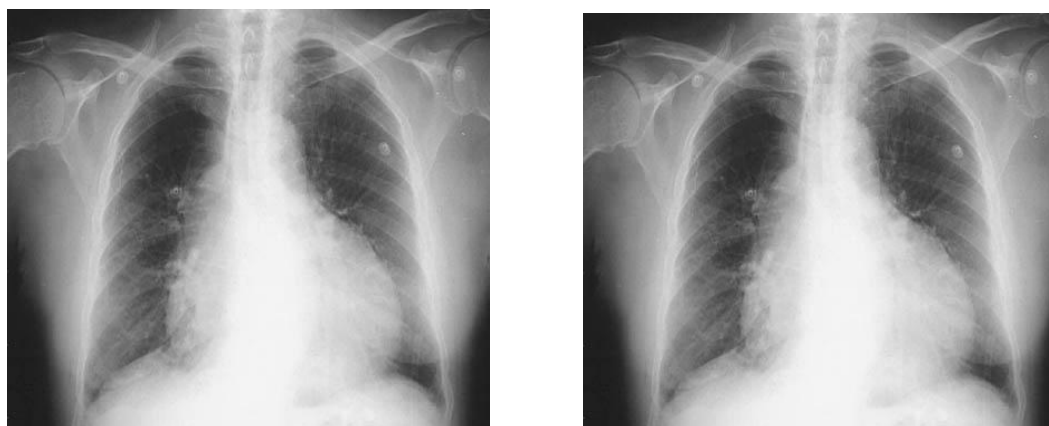
**Table 3.** Postoperative day of appearance, (n=209) by echocardiography M mode

<b>Post-operative day</b>	<b>7<sup>th</sup> day</b>	<b>10day</b>
Location of effusions{anterior\posterior}	Anterior\posterior{20\10}	Anterior\posterior{25\0}
Size of effusion	Small to moderate	large

**Figure 1.** Seeing that the value relevance of pericardial effusion and, therefore, the frequency and need for repeat studies have not yet to investigate the natural postoperative pericardial effusion



**Figure 2:** Chest X-ray



**Figure 3:** Posterior pericardial effusion impending tamponading

