

Case Report

Primary Hydatid Cyst of the Thigh , an unusual localization: a case report

Feras Almbaidin M.D1, Rami Qsous M.D2, Mutaz Alnaser M.D3, Abdullah Shawabkeh M.D4, Nidal Alsoud M.D5, Tamer Abdo M.D6, Ghaith Gsous MD7*

1. Specialist General Surgery, Royal Medical Services, Jordan.
2. Specialist Anaesthesia , Royal Medical Services, Jordan .
3. Specialist General Surgery , Royal Medical Services, Jordan .
4. Specialist General Surgery , Royal Medical Services, Jordan .
5. Specialist Anaesthesia , Royal Medical Services, Jordan .
6. Radiology Resident , Royal Medical Services, Jordan.
7. 5th year resident General Surgery , Royal Medical Services, Jordan.

*correspondence: **Ghaith Gsous**, 5th year resident General Surgery , Royal Medical Services.Email: gaithgsous@hotmail.com

Abstract:

Introduction: Subcutaneous musculoskeletal hydatid cysts are rare ,representing around 1-5%.It mimics a soft tissue tumor ,so preoperative radiological diagnosis is important to choose the treatment.

Case Presentation: This case was presented to clinic in Prince Ali Hospital in Karak . A 78 years old female patient was presented complaining of right medial thigh swelling which appeared a few weeks ago.The swelling caused discomfort and pain .On exam ,a lump was located in the medial aspect of the right thigh,round,soft,non mobile. Her US revealed multiple well defined cystic lesions in the posterior aspect of the thigh, with internal septae mostly representing a hydatid cyst. A MRI was ordered and showed a large,multi-lobular, thin walled and non-calcified fluid containing cyst. The appearance was consistent with a hydatid cyst.Next,the patient underwent a brain,chest and abdominal CT to check if there was a primary source,the results were negative.An Echinococcus Granulosa titer test was ordered, the result was negative. Treatment options were discussed.we preferred to start with the conservative approach.So,a high dose of Albendazole was started,with regular follow up in the clinic,but conservative treatment failed so we decided to continue with surgical treatment by complete excision.

Conclusion: Echinococcal disease should be considered in any patient who presents with a cystic mass despite body location. Especially in endemic areas.

Keywords: Hydatid Cyst, Thigh , Endemic area.

Introduction:

Hydatid Cyst is a parasitic disease caused by a tape worm of the Echinococcus type. The Echinococcus tapeworm has three layers (outermost is ectoderm, middle is mesoderm, inner is endoderm), characterized by absence of anus and digestive system. There are three main types of Echinococcus (E. granulosus – most common type, E. multilocularis, E. oligarthus), diseases caused by this tape worm as hydatid cyst are usually found in middle east, Africa and the western united states (1)(2).

Life cycle of Echinococcosis starts with the definitive host (dogs, wolves, foxes), the mature tapeworm lives in the small bowels of these animals and their eggs pass with the stool. Next step is ingestion the eggs by the intermediate hosts (sheep, pigs, goats, etc) and intermediate host could be human as well. The egg in the intermediate host attaches to the wall of small bowel and penetrates into blood and spreads to liver, lung, or any another organ and it is seated there and forms a bladder like structure, called Hydatid cyst (1).

Most common types in human are E. Granulosa and most common site of hydatid cyst is liver by 75%, followed by lung 15-5%, and can occur in other organs like heart, spleen, brain but in less possibility 10-20%, but there is very rare cases and location of hydatid cyst like muscles and subcutaneous tissue which was reported in less than 3% of cases. Presence of lactic acidosis in muscle creates a none preferable environment for hydatid cyst to form, therefore the muscle is considered a rare location for E.granulosa (1)(3).

So the presence of hydatid cyst in the subcutaneous tissue of the extremities is considered a rare condition. In literature, there are only a few reports about hydatid cysts in the chest wall, pectoralis major, biceps brachii (1).

Case Presentation:

This case was presented to general surgery clinic in Prince Ali Hospital in Karak a few months ago. A 78 years old female patient who is diabetic, hypertensive and with history of CVA, presented complaining of right medial aspect proximal thigh swelling which appeared few weeks before presentation, the swelling caused discomfort and minimal pain to the patient. On exam, the mass was found on the medial aspect of the right thigh proximally, the size was around 9 cm in diameter, round, soft, not tender, not mobile and with no skin changes. Her blood works were normal, she then underwent an ultrasound exam which revealed multiple well defined cystic lesions in the posterior aspect on the thigh, the largest was 10 cm in diameter and contained internal septae, these findings almost certainly represented a hydatid cyst. (figure 1) (figure 2). Afterwards, she underwent a MRI scan which revealed a large, multilobular, thin walled, non calcified fluid filled cyst, the classic appearance of a hydatid cyst (figure 3) (figure 4) (figure 5). Later on, the patient had a brain, chest and abdomen CT scans to check if there is a primary source and the result was negative. Then, we ordered the Echinococcus Granulosa titer and the result was negative (we mentioned before that this test is not specific for subcutaneous hydatid

cyst). The next step was to discuss the type of treatment, when considering the patient's co-morbidities, conservative therapy with Albendazole high dose for 1-2 months and follow up was decided on. 2 months after starting conservative treatment no response was noted. Accordingly, we decided to treat the patient surgically. The case and the co-morbidities were discussed with the anesthesiologist, the decision was made to operate using a local anesthetic. The cyst was excised completely (figure 6) but there was some spillage of the cyst content (daughter cysts and sand), so we gave the patient corticosteroids to prevent any allergic reaction from happening. The patient was discharged 2 days later. At her routine follow up clinics, the patient was doing well, had no complaints and the histopathology test confirmed our diagnosis.

Discussion:

The incidence of subcutaneous hydatid disease is very rare, around 1-5 %. It is more common in endemic areas. The well known echinococcus disease is more common in solid organ like the liver and lung. [3] [4] [5] [6]

The usual pathway for hydrated disease to develop in humans starts with the ingested ova penetrating the intestinal wall then entering the portal system reaching the liver (considered the first filter), few ova pass from the liver to reach the lung (the second filter) then they enter the systemic circulation where it can reach any organ, to the subcutaneous tissue of the thigh as in our case. [5]

Diagnosis of hydatid cyst disease starts with history and physical examination. It is usually found in endemic areas where sheep and dogs are more common inhabitants. The cyst itself is slow growing, soft, immobile and not attached to the skin .

Radiological assessment usually starts with an ultrasound, with a sensitivity of 95%, if vesicular fibrils are present ,the sensitivity increases to 100%. The US findings can be divided into 5 classes according to WHO , this cyst can be considered class CE3. A CT scansion then ordered to add more details about the cyst and to search for other sites of infestation (possible primary sources). The most accurate imaging study is the MRI which demonstrates most features of the hydatid disease, the cyst exhibits a hypo intense signal on T1W images and hyper intense signal on T2W images, denoting its fluid content, it also exhibits rim enhancement on Gadolinium enhanced T1 weighted images. [7] [8]

The best treatment option is to surgically excise the lesion after a course of albendazole. During the procedure ,it is preferred to irrigate the cavity with hypertonic saline and to avoid spilling any of the cyst's content, thus preventing an anaphylactic reaction and possible recurrence. [3].

Conclusion:

Musculoskeletal hydatid disease is a very rare entity. The differential diagnosis of any subcutaneous mass may include hydatid disease, specially in endemic areas where such disease is more common. The best

treatment option is complete surgical excision.

Acknowledgment:

Written consent was obtained from the patient and their relative for publication of the patients details.

References:

- 1- MemmetMihmanli , Ufuk Oguz Idiz , CemalKaya , EmreBozkurt . Current status of diagnosis and treatment of hepatic echinococcosis . world J hepatol . 2016 oct 8 ; 8 (28) : 1169 – 1181 .
- 2- Mandeep K Grg , Madhurima Sharma , Niranjankhandelwal . World J Radiol . 2016 jun 28 : 8 (6) : 581 – 587 .
- 3- Atmatzidid K , Papaziogas B , Tsiaousis P . Primary hydatid cyst of the thigh . Chirurgia (Bucur) . 2006 Jul – Aug ; 101(4):419-21 .
- 4- Orhan Z , Kara H , Tuzuner T , Alper M . Primary Subcutaneous Cyst hydatid disease in proximal thigh : an unusual localisation : a case

report . BMC Musculoskeletal Disord . 2003 Nov 7 ; 4 : 25 .

5- Abdelmalek Ousadden , Hisham Elbouhaddouti , Khalid AitTaleb . A solitary primary subcutaneous hydatid cyst in the abdominal wall of a 70 – year – old woman : a case report . J Med Case Reports . 2011 ; 5 : 270 .

6- Duygulu F , Karaoglu S , Erdogan N , Yildiz O . Primary hydatid cyst of the thigh : a case report of an unusual localization . Turk J Pediatr . 2006 Jul – Sep ; 48(3):256-9 .

7- Dr M Venkatesh . 2001 WHO Classification of hepatic hydatid cyst . [www.radiopedia.org / articles / world – health – organization – 2001 – classification – of – hepatic – hydatid – cysts .](http://www.radiopedia.org/articles/world-health-organization-2001-classification-of-hepatic-hydatid-cysts)

8- Turgut AT , Altin L , Kosar U . Unusual imaging characteristics of complicated hydatid disease . Eur J Radiol . 2007 Jul ; 63(1):84-93 Epub 2007 Feb 1.

Tables and Charts:

Figure 1: Ultrasound image of the right thigh showing a large well-defined cyst with internal incomplete septations, three smaller adjacent cysts are also seen.

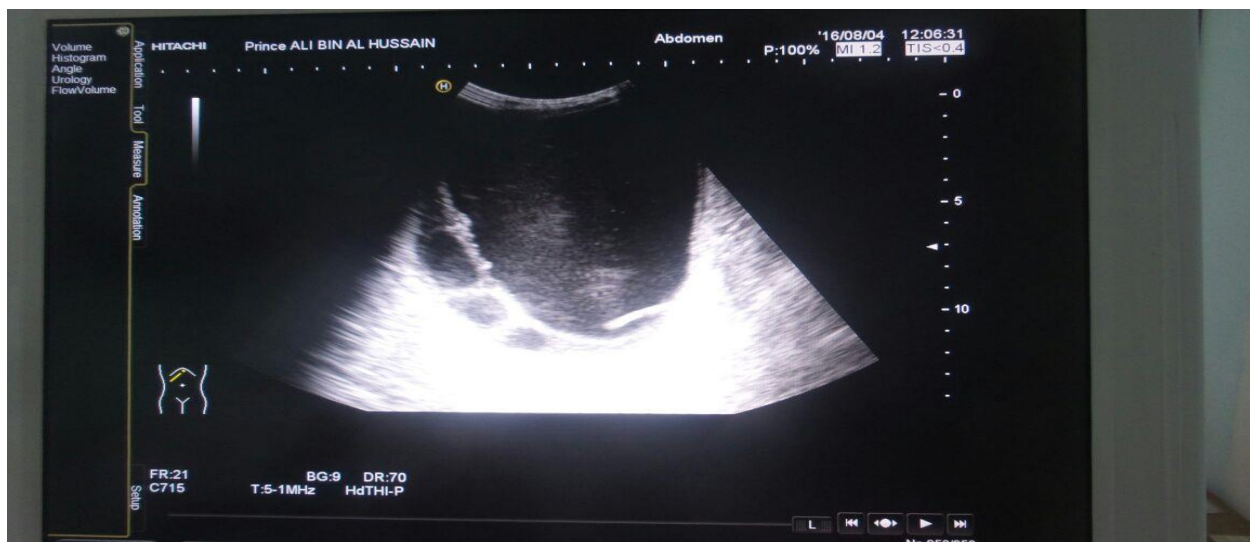


Figure 2: This picture demonstrates the incomplete internal septae more clearly.

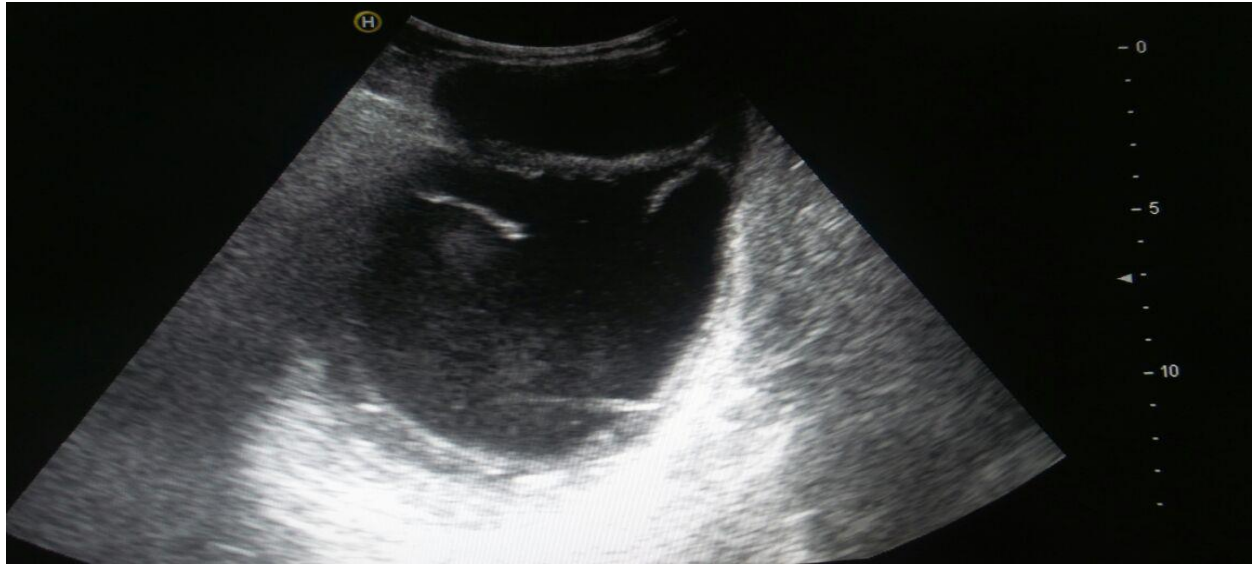

Figure 3: Axial T1W image of the upper thighs show a large well-defined cyst with multiple adjacent daughter cyst in the medial aspect of the right thigh with their content exhibiting a homogenous hypo intense signal.

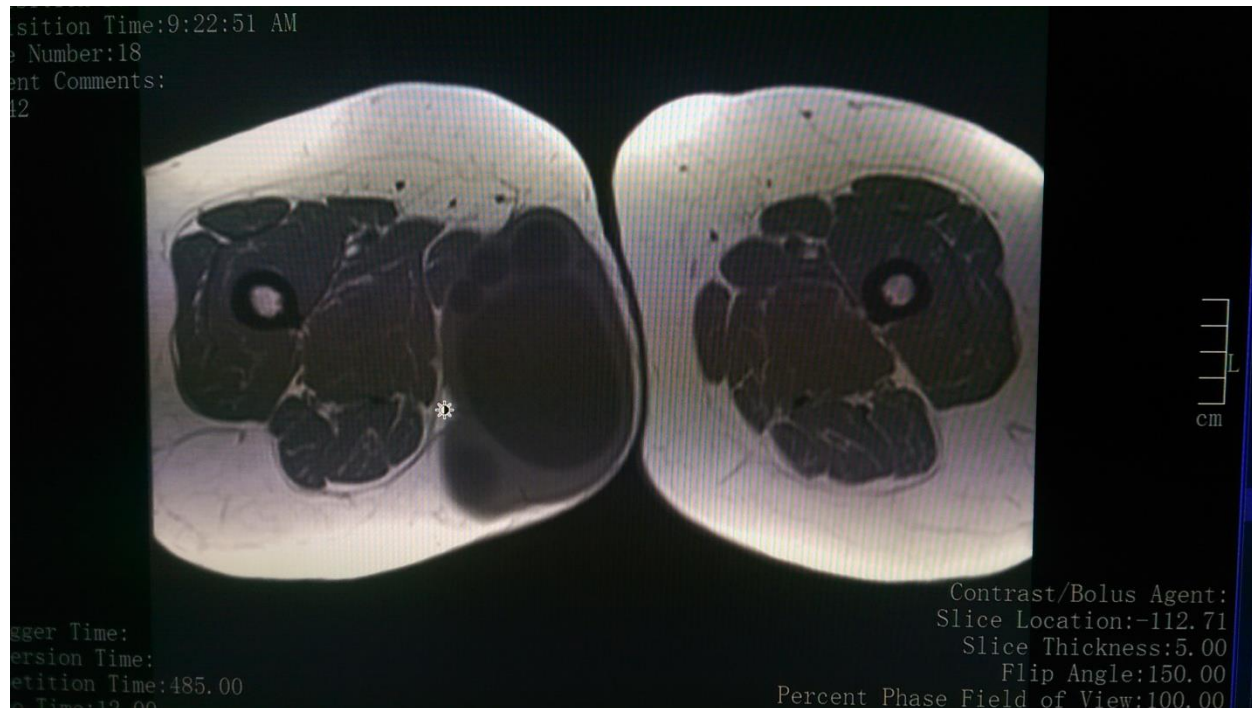

Figure 4: Axial T2W image of the upper thighs show a large well-defined cyst with multiple adjacent daughter cyst in the medial aspect of the right thigh with their content exhibiting a homogenous hyper intense signal.

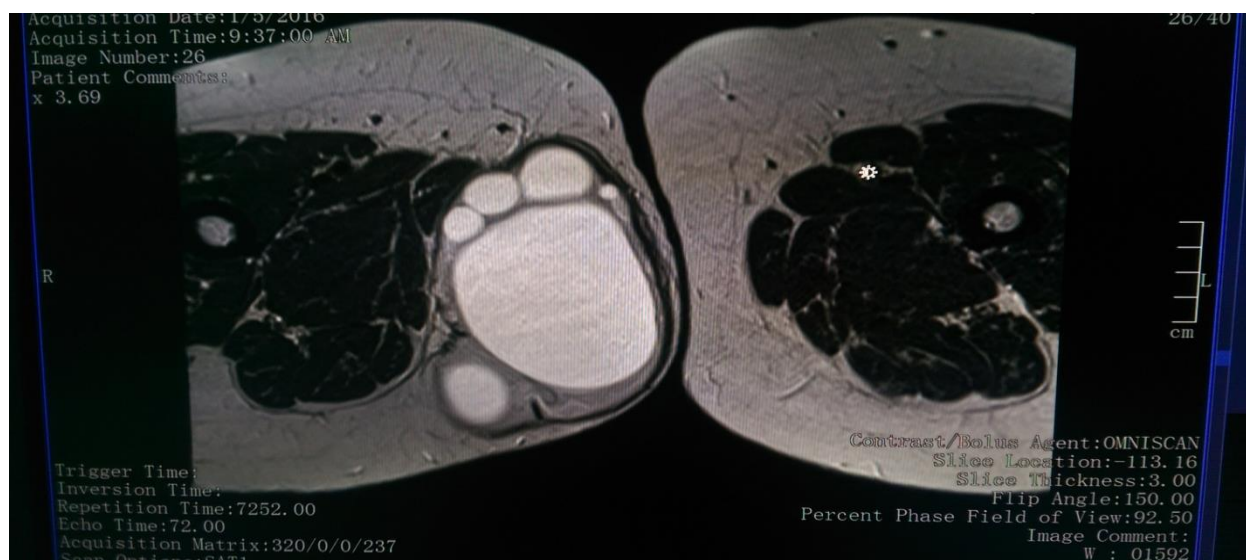


Figure 5: Coronal Gadolinium enhanced T1W images show rim enhancement of the cyst.

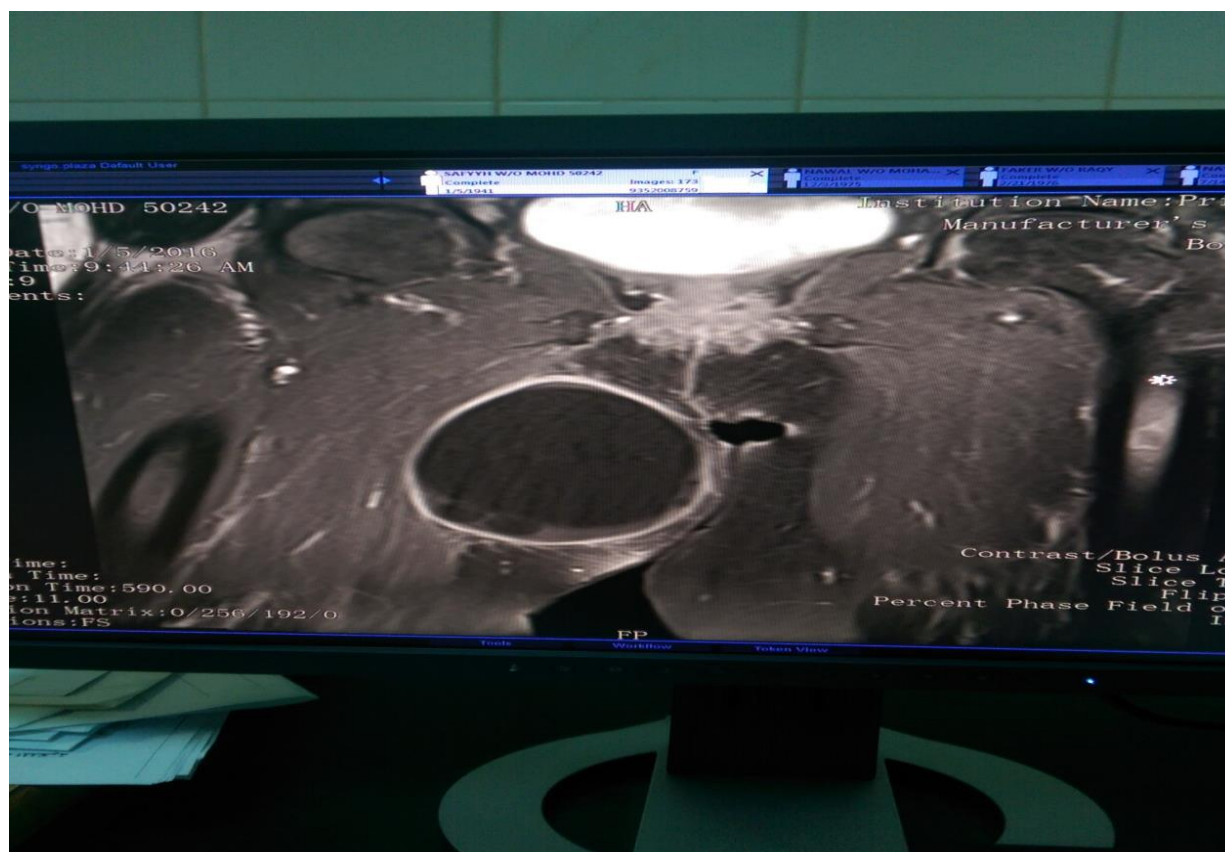


Figure 6: completely excised hydatid cyst.

