

Case Report

Treatment of acute antibody-mediated rejection using Rituximab

Saeid Amirkhanlou¹, Anna Rashedi², Mohammad Hadi Molseghi³, Mahdi babaei hatkehlouei⁴,
Mohsen Nafar⁵, Fatemeh Rezaghoulipoor⁵, Arash Rezaei Shahmirzadi^{6*}

1. Department of Nephrology, Clinical Research Development Unit (CRDU), Sayad Shirazi hospital, Golestan University of Medical Sciences, Gorgan, Iran.
2. Department of Radiology, Clinical Research Development Unit (CRDU), Sayad Shirazi hospital, Golestan University of Medical Sciences, Gorgan, Iran.
3. Medical Student, School of Medicine, Golestan University of Medical Sciences, Gorgan, Iran.
4. Dentistry student, student research committee, Mazandaran University of medical science, sari, Iran.
5. Chronic Kidney Disease Research Center and Department of Nephrology, Shahid Labbafinejad Medical Center and Shahid Beheshti University of Medical Sciences, Tehran, Iran
6. Student Research Committee, Faculty of Medicine, Golestan University of Medical Sciences, Gorgan, Iran.

Corresponding author:

Arash Rezaei Shahmirzadi

Student Research Committee, Faculty of Medicine, Golestan University of Medical Sciences, Gorgan, Iran.

Tel: +989112269189

E-mail: Arashrezaei198@yahoo.com

Abstract:

Introduction: One of the optimal therapies for most of the end-stage renal disease (ESRD) patients is transplantation. Acute Antibody Mediated Rejection is one type of acute rejection in which antibodies are directed against donor specific human leukocyte antigen (HLA). Rituximab is one kind of the drugs used for AMR treatment based on elimination of circulating Ab. It is a chimeric monoclonal Ab which is specific for human B lymphocyte– restricted differentiation antigen (CD20). Concerning the incidence of AMR in transplantation, existence of resistance to usual AMR therapy and their poor outcomes, we decided to use Rituximab (RTX) in treatment of AMR and to study its outcomes. **Material/Patients:** All patients who underwent renal transplantation from 2009 to 2014 in Chamran and Labbafinejad centers enrolled. these patients further receiving conventional therapy AMR (tacrolimus + Cellcept + corticosteroids ± PP), were treated with one or two dosage of RTX 500mg and the graft's response and the patient's response to RTX were studied. **Results:** After 5-11 months follow-up, patients' survival was 100% and grafts survival was 77%. In 17 patients renal function improved which the average creatinine (Cr) in the first month after treatment was 1.6 ± 0.5 ($P < 0.001$) and the average Cr in 6 month was 1.5 ± 0.8 ($P < 0.001$). **Conclusion:** In comparison with outcomes reported before in treatment of AMR, our study obtained excellent outcomes in patient and graft survival (100% and 77% respectively). Our findings suggest that the usage of RTX in the treatment of AMR at least in short and medium term may be effective.

Key Words: Rituximab, Renal Transplantation, Acute Antibody-Mediated Rejection

Introduction

One of the optimal therapies for most of the end-stage renal disease (ESRD) patients is transplantation which causes improvement of life quality and survival of these patients. Acute rejection (AR) is one of its complications that are associated with a high frequency of graft loss in some cases or graft dysfunction in others (1, 2). Acute Antibody Mediated Rejection (AMR) is one type of AR in which antibodies (Ab) are directed against donor specific human leukocyte antigen (HLA) molecules, blood group antigen (ABO)-isoagglutinins or endothelial cell antigens (3). The origin of Ab response is previous antigenic exposure (such as previous transplants, pregnancy and blood transfusions); this is the most common mechanism of occurring AMR (4).

AMR has three fundamental features: (a) functional evidence of allograft dysfunction, (b) morphological evidence of acute tissue injury and evidence of Ab-dependent activation of the classical pathway of the Complement system and (c) detection of circulating donor specific Ab (DRSA) (5). This condition occurs in approximately 5.6% to 23% of unselected populations (6) and 30% to 60% of patients undergoing preconditioning for ABO-incompatible transplantation or transplantation across a positive donor specific cross-match (4-6). AMR treatment is based on T-cell response suppression (7, 8), circulating Ab elimination (2), residual Ab inhibition (3), B-cells Suppression or depletion (6).

Rituximab is one kind of the drugs used for AMR treatment based on elimination of circulating Ab. It is a chimeric monoclonal Ab composed of human IgG1 heavy chain and kappa light chain constant regions which is specific for human B lymphocyte-restricted differentiation antigen (CD20) (9).

This antigen is a hydrophobic trans-membrane protein that is expressed on pre-B-lymphocytes and mature B-lymphocytes throughout the development in its antigen-independent stage until the early stages of antigen-dependent B-cell activation (10). The Ab-dependent cell cytotoxicity (ADCC) is the main mechanism of rituximab-induced depletion in vivo (10-12); although complement-dependent cell killing and induction of apoptotic death are also important mechanisms (12).

Few protocols have used rituximab in treatment of AMR; so its efficacy for AMR therapy is poorly understood. Altogether, flaws in rituximab usage in transplantation and its efficacy in treatment of other Ab-mediated diseases implicate rituximab effectiveness as an adjuvant agent for injuries mediated by Ab in grafts (13-15). Concerning the incidence of AMR in transplantation, existence of resistance to usual AMR therapy and their poor outcomes, we decided to use Rituximab (RTX) in treatment of AMR and to study its outcomes.

Patients and Methods:

All patients who underwent renal transplantation from 2009 to 2014 in Chamran and Labbafinejad centers, whom were experiencing an acute rise in serum creatinine during the first month after transplantation and according to renal biopsy had all criteria for AMR, and whom had no response to routine treatments after a week, if they can afford the price of Rituximab (RTX) after giving some explanations and taking satisfaction enrolled. Sampling method was simple sampling and based on the inclusion criteria. All transplanted patients who were eligible selected as a sample. 19 patients were examined and the results reported. Biopsy

results were assessed according to Banff 2013. Patients GFR were calculated according to the formula MDRD.

Inclusion and exclusion criteria: All kidney transplant patients with acute rejection (laboratory and pathology According to AMR to them) and not respond to usual therapy were enrolled. Patients with other diagnoses depending on the transplanted kidney failure were excluded.

Treatment: After explaining, these patients further receiving conventional therapy AMR (tacrolimus + Cellcept + corticosteroids \pm IVIG daily at a dose of 100 for 5 days \pm PP), were treated with one or two dosage of RTX 500mg and the graft's response and the patient's response to RTX according to renal functional criteria with Cr, patients survival and graft in the short term (weeks - months - 3 months and 6 months after treatment) were studied.

The required information, data collected by a nephrologist (based of the information in the file archive and clinic files and follow-up of the patients' files in clinic by informational form). Patients Creatinine (Cr) measured by a laboratory recorded before and after treatment. In the current study, all 19 cases were treated by RTX were considered for final sample. The data of the study after collecting analyzed using SPSS version 18. Quantitative data in the 2 groups, analyzed by (student t test) and the results reported as (Significant) with considering the P value less than 0.05.

Results

During this period a total of only 19 patients (9 women and 10 men) with a diagnosis of AMR that 11 cases (58%) were CD⁴ positive and 8 cases (42%) were CD⁴ negative. 11 patients were positive for Anti HLA Ab.

Of these 19 patients, 1 was third transplanted, 8 were second transplanted and 10 were first transplanted. All patients except two cases were transplanted from a live donor. Between the first and second week after transplant renal biopsy was performed.

Histology of renal biopsy was reported by a pathologist according to Banff 07 criteria. 13 were grade 2, 5 were grade 3 and 1 was grade 1. 4 patients plasmapheresed at least 5 sessions. All patients initially received intravenous corticosteroid pulse (250-500mg daily for 3-5 consecutive days). Because of being high risk patients received ATG from the beginning.

All patients were shifted from CSV to tacrolimus and all patients sustaining immunosuppression was (corticosteroid + celecept + tacrolimus). After 1 week 2 doses of RTX (375 mg/m²) calculated and injected to all 19 patients.

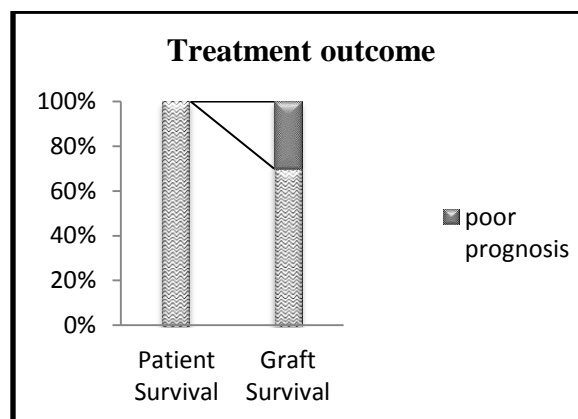


Figure 1: patient's survival and grafts survival in patients.

After 5-11 months follow-up, patients' survival was 100% and grafts survival was 77 % (Fig 1). 2 patients lost the graft and placed on dialysis treatment. In 17 patients renal function improved which the average creatinine (Cr) in the first month after treatment was ($P < 0.001$) 1.6 ± 0.5 and the

average Cr in 6 month was 1.5 ± 0.8 ($P < 0.001$).

None of the 19 patients receiving RTX show hypersensitivity and significant hypotension and patients had good tolerance to the drug.

Within 3 years, 6 graft rejection causes by antibody were reported in transplanted patients who were undergoing by other treatments like ATG and PP and pulse corticosteroid and interestingly the four of them during 1 to 3 month after graft rejection required chronic hemodialysis.

Unfortunately, due to lack of Cd4 staining at that time, lack of pathology block, lack of adequate information, heterogeneous group of patients and insufficient number of samples possibility of comparing as a control group was not available.

Another point in our study was inability to measure the Donor Specific Antibody which was used from Anti HLA Antibody positive or negative as reagents.

Discussion

In this study we treated 19 cases of AMR with 2 doses of RTX (375 mg/m^2 body surface area) in addition to common treatments like PP, IVIG, corticosteroids, ATG and shift to stronger IS's (tacrolimus). In a short time (1 month), 17 patients recovered and Cr improved in them (graft survival=77% and average Cr = 1.6) and this result was observed in 16 patients at 11 months after treatment in maximum. As it is evident from the results, in patients with over 1 transplantation who had AMR and required dialysis, response to treatment was lower. From 8 patients of second transplantation, just one case recovered but this condition over years increased the Cr to 3.5.

In Becker et al study, single dose of rituximab 375 mg/m^2 body surface area in 27 sensitized patients with refractory acute rejection (not responding to combination therapy with ATG and PP or high-dose intravenous steroids) was used and it caused in rejection reversion; however, serum creatinine increased impressively (5.6 ± 1.0 to $0.95 \pm 0.7 \text{ mg/dL}$; $P < 0.001$) (2). Johns Hopkins Incompatible Transplant Program showed that rituximab has significant effect in reduction of PE treatments which are essential for achieve AMR resolution, in dispense with AMR in conditions there are poor outcomes or refractory to low-dose CMV-Ig and PE therapy and in AMR caused by anti-HLA Ab and antiisoagglutinins (1,3,4).

Combination of rituximab with IVIg and steroids or with IVIg, steroids and PE in AMR highly sensitized recipients, indicated a 50% to 100% resolution of rejection and 100% survival of graft and patient (6). Combination of rituximab with PE and IVIg in other solid organ transplants with AMR suggested that this protocol could be effective for early and late pancreas and cardiac allograft rejection therapy, respectively (16, 17). It is reported recently by Faguer et al that two patients of 8 kidney transplant recipients whom treated with rituximab, PE and antilymphocyte Ab, did not get raised the diagnostic criteria for AMR. In all of these patients, after 10 months follow-up, this treatment protocol accompanied with 75% rejection reversal, 25% graft loss and 1.73 mg/dl median serum creatinine. In one case, allograft rejection occurred (18).

It has been indicated that rituximab therapy is associated with polyoma virus infection and some other complications (namely severe infections, septic shock, and fungal polynephritis) (13-18). Comparison between high-dose IVIg therapy and PP low-dose IVIg-rituximab therapy efficacy has showed

that the first protocol was accompanied with negative cross-match in 38% of patients while the second one had negative cross-match in 84% and 88% of patients. Although any of these regimens did not prevented AMR occurrence, PP low-dose IVIg-rituximab therapy led to lower AMR rates than high dose IVIg (19).

Depletion of naive B-cells by rituximab has been reported which is the main reason why rituximab is relatively successful in AMR treatment (7, 14). It is said that this agent does not have any effect on plasma cells; so rituximab can affect Ab production independent from Ab producing cells suppression or depletion, in particular those producing Ab against antigens which are t-cell dependent (3,8,15). Right dosing for rituximab therapy and its length of therapy are two important factors for this kind of AMR treatment. It is suggested that a single dose of rituximab (50 mg/m² body surface area) has same effects on B-cells depletion and high panel-reactive antibody (PRA) as higher doses (150 and 375 mg/m² body surface area) but it is not clear if multiple doses of this agent would have better outcomes than usual doses of it (18-20).

Conclusion

This study is a small review on the experience of usage of RTX on AMR treatment. After renal transplantation AMR is a serious problem, but early detection and early treatment with combination therapies by IVIG, PP and RTX often leads to improvement. In comparison with outcomes reported before in treatment of AMR, our study obtained excellent outcomes in patient and graft survival (100% and 77% respectively). Our findings suggest that the usage of RTX in the treatment of AMR at least in short and medium term may be effective.

The small sample size and lack of control group didn't allow us to conclude definitively regarding the effectiveness of the treatment. It is suggested to do a study with a control group and sufficient samples and enough time to follow up.

Acknowledgements:

The authors gratefully thank the patients for their cooperation and thoughtful responses.

Conflict of interest

The authors declare that they have no conflict of interests.

References:

1. Warren DS, Zachary AA, Sonnenday CJ, et al. Successful renal transplantation across simultaneous ABO incompatible and positive crossmatch barriers. *Am J Transplant* 2004;4:561-8.
2. Becker YT, Becker BN, Pirsch JD, Sollinger H. Rituximab as treatment for refractory kidney transplant rejection. *Am J Transplant* 2004;4:996-1001.
3. Montgomery RA, Simpkins CE, Zachary AA, et al. Anti-CD20 rescue therapy for kidneys undergoing antibody-mediated rejection. *Am J Transplant* 2004;4(Suppl 8):258.
4. Samaniego M, Zachary AA, Lucas D, et al. Early allograft outcomes in patients with antibody mediated rejection treated with rituximab: a single center experience. *Am J Transplant* 2002;2(Suppl 3):259.
5. Macklin PS, Morris PJ, Knight SR. A systematic review of the use of

- rituximab for the treatment of antibody-mediated renal transplant rejection. *Transplant Rev (Orlando)*. 2017 Jan 24. pii: S0955-470X(16)30114-8.
6. Peng A, Vo A, Bunnapradist S, Toyoda M, Jordan S. Incidence and outcomes of treatment protocols for antibody-mediated rejection in highly sensitized patients transplanted using desensitization therapy. (Abstract) *Am J Transplant and Transplantation 2006(World Transplant Congress 2006)*:259.
 7. Melcher ML, Olson JL, Baxter-Lowe LA, Stock PG, Posselt M. Antibody-mediated rejection of a pancreas allograft. *Am J Transplant* 2006; 6:423-8.
 8. Gubensek J, Buturovic-Ponikvar J, Kandus A, Arnol M, Lindic J, Kovac D, Rigler AA, Romozi K, Ponikvar R. Treatment of Antibody-Mediated Rejection After Kidney Transplantation - 10 Years' Experience With Apheresis at a Single Center. *Ther Apher Dial*. 2016 Jun;20(3):240-5.
 9. Baran DA, Lubitz S, Alvi S, et al. Refractory humoral cardiac allograft rejection successfully treated with a single dose of rituximab. *Transplant Proc* 2004; 36:3164-6.
 10. Faguer S, Kamar N, Guilbeaud-Frugier C, et al. Rituximab therapy for acute humoral rejection after kidney transplantation. *Transplantation* 2007; 83:1277-80.
 11. Surendra M, Raju SB, Raju N, Chandragiri S, Mukku KK, Uppin MS. Rituximab in the treatment of refractory late acute antibody-mediated rejection: Our initial experience. *Indian J Nephrol*. 2016 Sep;26(5):317-321.
 12. Stegall MD, Gloor J, Winters JL, Moore SB, DeGoey S. A comparison of plasmapheresis versus high-dose IVIg desensitization in renal allograft recipients with high levels of donor specific alloantibody. *Am J Transplant* 2006; 6:346-51.
 13. Roll P, Palanichamy A, Kneitz C, Dorner T, Tony H. Regeneration of B cell subsets after transient B cell depletion using anti-CD20 antibodies in rheumatoid arthritis. *Arthritis Rheum* 2006; 54: 2377-86.
 14. Sidner RA, Book BK, Agarwal A, Bearden CM, Vieira CA, Pescovitz M. In vivo human B-cell subset recovery after in vivo depletion with rituximab, anti-human CD20 monoclonal antibody. *Hum Antibodies* 2004; 13:55-62.
 15. Lachmann N, Duerr M, Schönemann C, Pruß A, Budde K, Waiser J. Treatment of Antibody-Mediated Renal Allograft Rejection: Improving Step by Step. *J Immunol Res*. 2017;2017:6872046.
 16. Garces JC, Giusti S, Staffeld-Coit C, Bohorquez H, Cohen AJ, Loss GE. Antibody-Mediated Rejection: A Review. *Ochsner J*. 2017 Spring;17(1):46-55.
 17. Shapiro-Shelef M, Calame K. Plasma cell differentiation and multiple myeloma. *Curr Opin Immunol* 2004; 16:226-34.
 18. Vieira CA, Agarwal A, Book BK, et al. Rituximab for reduction of anti-

- HLA antibodies in patients awaiting renal transplantation: 1. Safety, pharmacodynamics and pharmacokinetics. *Transplantation* 2004; 77:542-8.
19. Hogen R, DiNorcia J, Dhanireddy K. Antibody-mediated rejection: what is the clinical relevance? *Curr Opin Organ Transplant*. 2017 Apr;22(2):97-104.
20. Nin M, Coitiño R, Kurdian M, Orihuela L, Astesiano R, Garau M, López D, Rievas G, Rodriguez I, González-Martínez F, Noboa O. Acute Antibody-Mediated Rejection in Kidney Transplant Based on the 2013 Banff Criteria: Single-Center Experience in Uruguay. *Transplant Proc*. 2016 Mar;48(2):612-5.