

Case report

Case report: A 27 years old woman with brain metastases of synovial sarcoma

Nosrati Anahita ¹, Shafiee Sajad ², Emadi Aazam ³

1. Department of pathology, Gastrointestinal cancer register center, Imam Khomeini hospital, Mazandaran university of medical sciences, Sari, Iran.

2_ Department of neurosurgery, Imam Khomeini hospital, Mazandaran university of medical sciences .Sari, Iran.

3_ Department of pathology, Imam Khomeini hospital, Mazandaran university of medical sciences.
, Sari, Iran.

Corresponding author: Sajad Shafiee

Email: sajad.shafiee@gmail.com

Abstract

A 27- year old lady with severe headache, nausea, vomiting and impaired cerebellar function. She had a history of a left arm synovial sarcoma and she was evaluated with magnetic resonance imaging (MRI) that shows a gadolinium enhanced mass measuring about 7 mm in diameter with both solid and cystic portions in left cerebellar hemisphere causing mass effect. Histologic evaluation confirmed poorly differentiated type synovial sarcoma composed of tumor cells containing pleomorphic round to oval hyper chromatic to vesicular nuclei with coarse chromatin and a little light eosinophilic cytoplasm. The IHC stain is done and showed EMA, CK and vimentin positivity in tumor cells. The patient was treated with surgery, chemotherapy and radiotherapy. In the follow up study at 6 month post chemotherapy evaluation computed tomography (CT scan) showed pulmonary metastases and transthoracic biopsy revealed the same pathologic feature. According to our patient, brain metastasis could occur even in extremities synovial sarcoma and so CNS imaging as screening may be introduced in follow up plan of these patients.

Keywords: *synovial sarcoma, brain metastases, pulmonary metastases.*

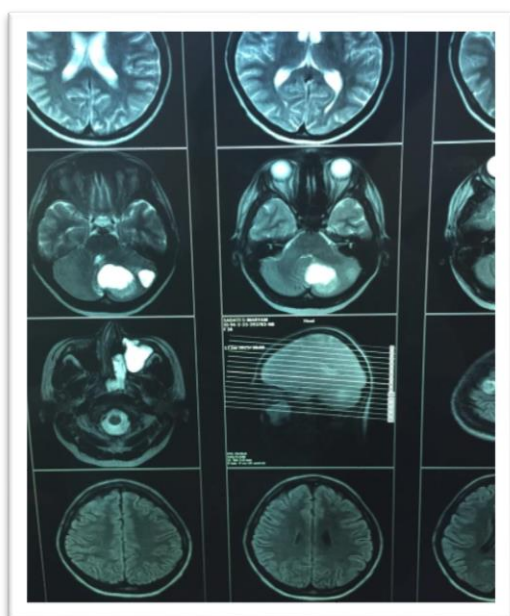
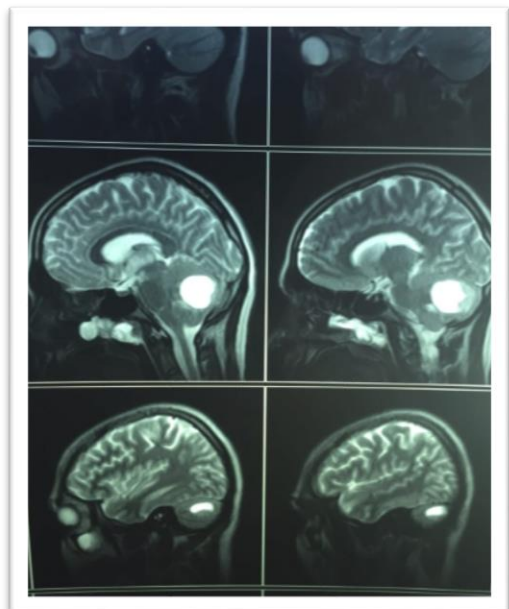
Introduction

Synovial sarcoma (SS) is a high-grade, malignant soft tissue sarcoma accounting for 5%–10% of soft tissue sarcomas (1–3). After rhabdomyosarcoma, SS is the most common soft tissue sarcoma in children, adolescents, and young adults (1). The term Synovial sarcoma is derived from the morphological similarity to the embryonic synovium (2, 3) and is often misinterpreted to as the tumor originates from synovial tissue, which is not the case (3–5). Synovial sarcoma has been proposed to stem from myogenic cell lines (5) and occurs in soft tissues almost anywhere in the body, most frequently in the lower (62%) and upper (21%) extremities (6, 7). Histologically, these tumors are classified as

biphasic, monophasic (purely epithelioid or fibroblastic), or poorly differentiated (8). SS is associated with local recurrence and distant metastases. Metastasis occurs in 50%–70% of cases. Since these tumors grow slowly, they have a high incidence of late metastases (1) The most common site for metastasis is the lung, followed by lymph node involvement. Synovial sarcoma rarely metastasizes to the skeleton and when it occurs, it most commonly involves the long bones(9) cranial metastasis is rare .Here we describe a case of intracranial metastases of a synovial sarcoma.

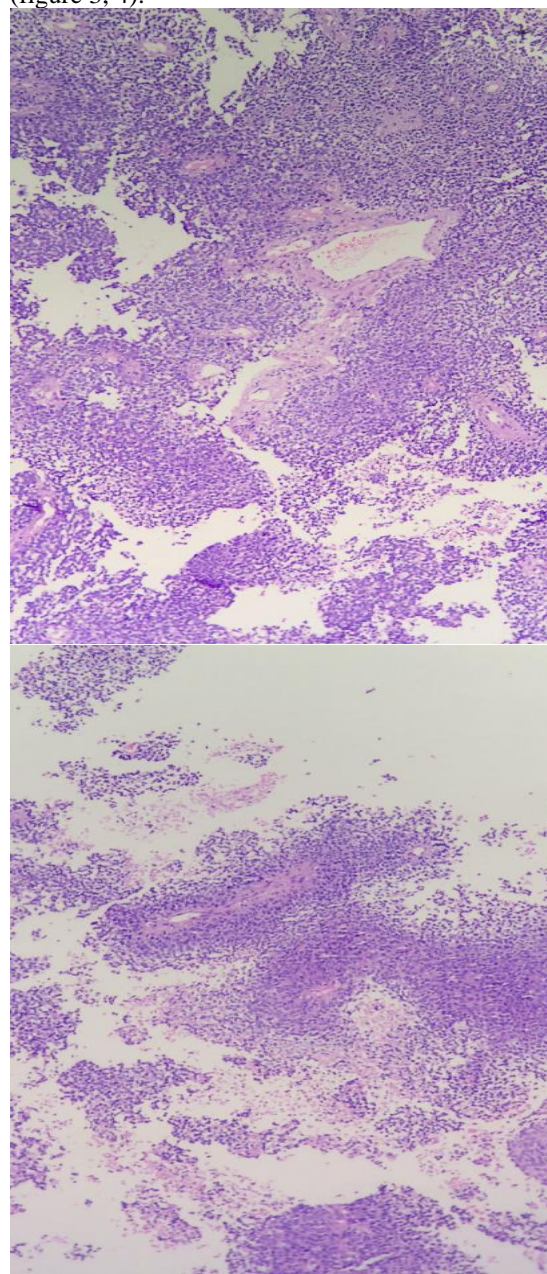
Case report

A 27- year old lady was admitted in our hospital with severe headache, nausea, vomiting and impaired cerebellar function; she had a history of a left arm synovial sarcoma and underwent surgery, chemotherapy and external beam radiation 2 years ago. The patient was evaluated with magnetic resonance imaging (MRI) that shows a gadolinium enhanced mass measuring about 7 mm in diameter with both solid and cystic portions in left cerebellar hemisphere causing mass effect.(figure 1,2).



Open biopsy of intracranial mass confirmed poorly differentiated type synovial sarcoma composed of tumor cells containing pleomorphic round to oval

hyper chromatic to vesicular nuclei with coarse chromatin and a little light eosinophilic cytoplasm (figure 3, 4).



The IHC stain is done and showed EMA, CK and vimentin positivity in tumor cells.

The patient was treated with surgery, chemotherapy and radiotherapy. In the follow up study at 6 month post chemotherapy evaluation computed tomography (CT scan) show pulmonary metastases and transthoracic biopsy reveal the same pathologic feature (figure5).

Discussion

Synovial sarcoma is a well-defined clinical and morphological entity that is originally described by Simon in 1865 and named in 1934 by Sabrazes(10)

because of its resemblance to developing synovial tissue under light microscope. The term “synovial sarcoma” is however a misnomer as the tumor cells do not share the same immune histochemical and ultrastructural features of the normal synovium. The cellular origin of this tumor is probably considered as neural crest derived cells(11). Synovial sarcoma has a unique metastatic pattern. Unlike many other sarcomas, it is not uncommon for it to metastasize to the lymph nodes, other soft tissues, and on occasion, bone. Regional lymph node involvement has been reported in 3% to 10% of patients, and some have suggested performing sentinel lymph node biopsy to assist in staging (12,13). Several cases of head and neck metastasis are reported in the literature; however brain metastasis is exceptionally rare (14-16).

Otani et al reported a 41-year-old woman with brain metastases of synovial sarcoma who was admitted with sensory aphasia. But she had a history of a left inguinal synovial sarcoma and underwent surgery and chemotherapy for primary and metastatic lesions. She received cyber-knife radiosurgery and her neurological deficit was almost completely resolved (17).

Siegel et al presents a case of a 17-year-old adolescent boy who presented with simultaneous enlarging masses involving the skull and thigh. Open biopsies confirmed synovial sarcoma in both regions(18).

Paras Nuwal et al reported a case of primary monophasic synovial sarcoma of lung presenting with brain metastasis in a 35-year-old male patient. The diagnosis was made on percutaneous transthoracic needle aspiration from left-sided pulmonary mass and later confirmed by immunohistochemistry(19).

Several cases of head and neck metastasis are reported in the literature; however brain metastasis is exceptionally rare. A delay in diagnosis is also common with synovial sarcoma, because of their insidious onset, periarticular location and often benign appearing imaging features. Additionally, intralesional calcification may be seen on radiographs in up to 20% of synovial sarcoma. This finding may be confused with such entities as myositis ossificans, extraskeletal osteosarcoma, mesenchymal chondrosarcoma and sclerosing lipoma(20).

According to our patient, brain metastasis could occur even with extremities synovial sarcoma and so CNS imaging as screening may be introduced in follow up plan of these patients.

References

1. Weiss S, Goldblum J, Publishing M. Enzinger and Weiss's Soft Tissue Tumors. St Louis, MI: Mosby 2001.

2. Milchgrub S, Ghandur-Mnaymneh L, Dorfman HD, Albores-Saavedra J. Synovial sarcoma with extensive osteoid and bone formation. *Am J Surg Pathol* 1993; 17: 357–363.

3. Miettinen M, Virtanen I. Synovial sarcoma—a misnomer. *Am J Pathol* 1984; 117: 18–25.

4. Smith ME, Fisher C, Wilkinson LS, Edwards JC. Synovial sarcoma lack synovial differentiation. *Histopathology* 1995; 26: 279–281.

5. Halder M, Hancock JD, Coffin CM et al. A conditional mouse model of synovial sarcoma: insights into a myogenic origin. *Cancer Cell* 2007; 11: 375–388.

6. Lewis JJ, Antonescu CR, Leung DH et al. Synovial sarcoma: a multivariate analysis of prognostic factors in 112 patients with primary localized tumors of the extremity. *J Clin Oncol* 2000; 18: 2087–2094.

7. Okcu MF, Munsell M, Treuner J et al. Synovial sarcoma of childhood and adolescence: a multicenter, multivariate analysis of outcome. *J Clin Oncol* 2003; 21: 1602–1611.

8. Fletcher CDM, Unni KK, Mertens F. World Health Organization Classification of Tumours: Pathology and Genetics of Tumours of Soft Tissue and Bone. Lyon, France: IARC Press 2000.

9. 1. Spillane AJ, A'Hern R, Judson IR, Fisher C, Thomas JM. Synovial sarcoma: a clinicopathologic, staging and prognostic assessment. *J Clin Oncol* 2000; 18(22):3794-3803.

10. Sabrazes J, Loubat E, de Grially R, Magendie J. Synovial sarcomas. *Gaz Hebdomadaire de Médecine de Bordeaux*. 1934;55:754–62.

11. Rong R, Doxtader EE, Tull J, de la Roza G, Zhang S. Metastatic poorly differentiated monophasic synovial sarcoma to lung with unknown primary: A molecular genetic analysis. *Int J Clin Exp Pathol*. 2010;3:217–21. [PMC free article] [PubMed]

12. Blazer DG III, Sabel MS, Sondak VK. Is there a role for sentinel lymph node biopsy in the management of sarcoma? *Surg Onc*. 2003; 12(3):201-206.

13. Stojadinovic A, Leung DH, Allen P, Allen P, Lewis JJ, Jaques DP, Brennan MF. Primary adult soft tissue sarcoma: time dependent influence of prognostic variables. *J Clin Oncol*. 2002; 20(21):4344-4352

14. Utsunomiya A, Kinouchi H, Kayama T, Yoshimoto T. Distant metastasis of liposarcoma to the dura and skull: a case report. *Br J Neurosurg*. 1999; 13(5):520-522.

15. Takamiya Y, Toya S, Iizaka Y, Otani M, Takenaka N, Imanishi T. Intracranial metastasis of

soft tissue fibrosarcoma- a case report. *Neurol Med Chir.* 1986; 26(1):54-57.

16. Lefkowitz NW, Roessmann U, Kori SH. Major cerebral infarction from tumor embolus. *Stroke.* 1986; 17(3):555-557.

17. Otani Y1, Ichikawa T, Kurozumi K, Yanai H, Kunisada T, Ozaki T, Date I. A case of synovial sarcoma with brain metastasis treated with surgical resection and stereotactic radiosurgery. *No Shinkei Geka.* 2013 Mar;41(3):255-62.

18. Siegel HJ1, Dunahm WH, Lopez-Ben R, Siegal GP. Intracranial metastasis from synovial sarcoma. *Orthopedics.* 2008 Apr;31(4):405.

19. Paras Nuwal, Ramakant Dixit, Narender Singh Shah, and Anil Samaria. Primary monophasic synovial sarcoma lung with brain metastasis diagnosed on transthoracic FNAC: Report of a case with literature review. *Lung India.* 2012 Oct-Dec; 29(4): 384–387.

20. Herrick J. Siegel, MD; William H. Dunham, MD; Robert Lopez-Ben, MD; Gene P. Siegal, MD, PhD. Intracranial metastasis from synovial sarcoma. *Orthopedics.* 2008 April; 31(4):